

# Radiation contouring guidelines for non-germinomatous germ cell tumors

Children's Oncology Group  
Guide for Protocol  
ACNS2021

*Version date: September 2023*

# Collaborators

Shannon MacDonald<sup>1</sup>, Erin Murphy<sup>2</sup>, Matthew D. Hall<sup>3</sup>,  
Derek S. Tsang<sup>4</sup>, Robert Lavey<sup>5</sup>, David Morris<sup>6</sup>, Thomas  
Merchant<sup>7</sup>, Bernadine Donahue<sup>8</sup>

Massachusetts General Hospital<sup>1</sup>, Cleveland Clinic Foundation<sup>2</sup>, Miami Cancer  
Institute<sup>3</sup>, Princess Margaret Cancer Centre<sup>4</sup>, Moffit Cancer Center<sup>5</sup>, University of  
North Carolina at Chapel Hill<sup>6</sup>, St. Jude's Children's Research Hospital Memphis<sup>7</sup>,  
New York University<sup>8</sup>

# Atlas sections

- a) Whole ventricular
- b) Biopsy tract
- c) Spinal canal (thecal sac)

Please refer to ACNS2021 protocol for full written guidelines

Whole ventricular

Section a)

# General Guidelines

- Planning CT should be fused to a pre-radiation T2 MRI sequence for delineation of the whole ventriclular volume (WVV)
- The WVV is considered a Clinical Target Volume (CTV)
- The involved field CTV should be delineated upfront and encompassed in the WVV volume to ensure full dose to the involved field boost

# General Guidelines

- The WVV should encompass the lateral, third, and fourth ventricles
- Care should be taken to ensure the prepontine, suprasellar and pineal cisterns are included in the WVV
- Inclusion of the prepontine cistern is required for patients treated on ACNS2021

# General Guidelines

- Expand the WVVCTV (including prepontine cistern) geometrically by 3 or 5 mm to create the WVVPTV

# Lateral Ventricles

- The lateral ventricles contain 3 horns; the frontal (anterior) horns, the temporal (inferior horns), and the occipital (posterior) horns
- The lateral ventricles connect to the third ventricle through the foramina of Monro



# Third Ventricle

- Midline between lateral ventricles
- Communicates with the lateral ventricles through the foramina of Monro
- Communicates with the 4<sup>th</sup> ventricle through the cerebral aqueduct (of Sylvius)
- Anterior floor is a barrier to the pre-pontine cistern that is opened by a third ventriculostomy procedure

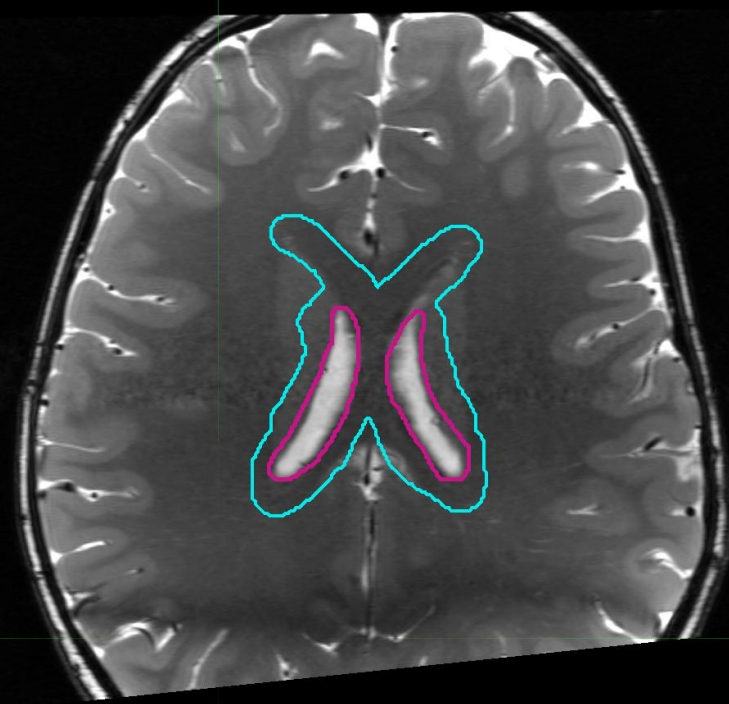
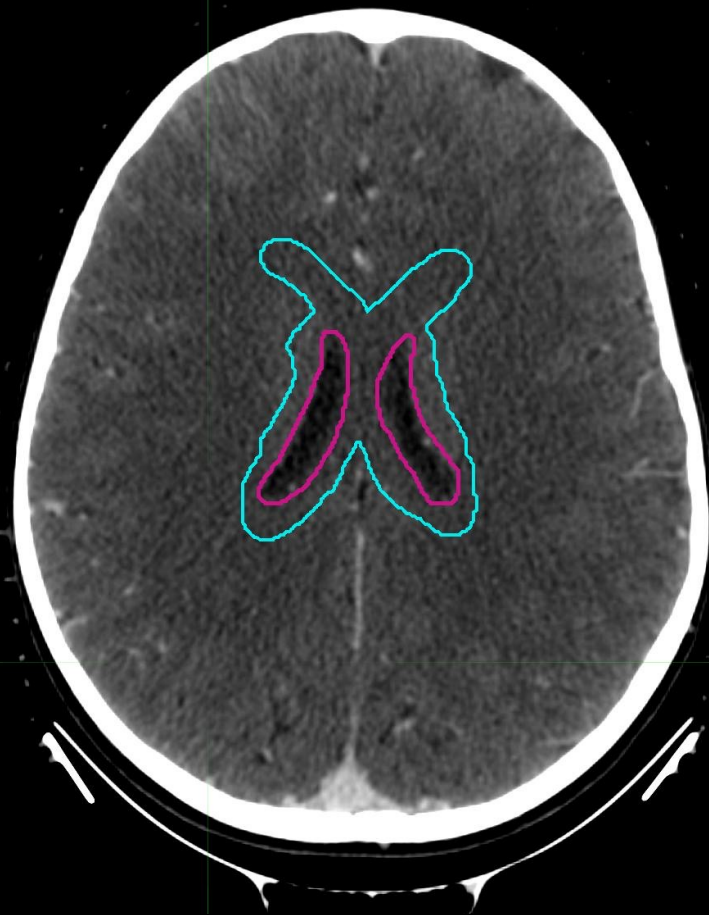# Third Ventricle

- The third ventricle protrudes anteriorly to form the supraoptic and infundibular recesses (suprasellar cistern)
- The third ventricle protrudes posteriorly to form the suprapineal and pineal recesses (pineal cistern)

# Fourth Ventricle

- Communicates with the 3<sup>th</sup> ventricle through the cerebral aqueduct (of Sylvius)
- Communicates with the prepontine space through the foramina of Luschka
- Communicates with the spinal canal through the foramen of Magendie

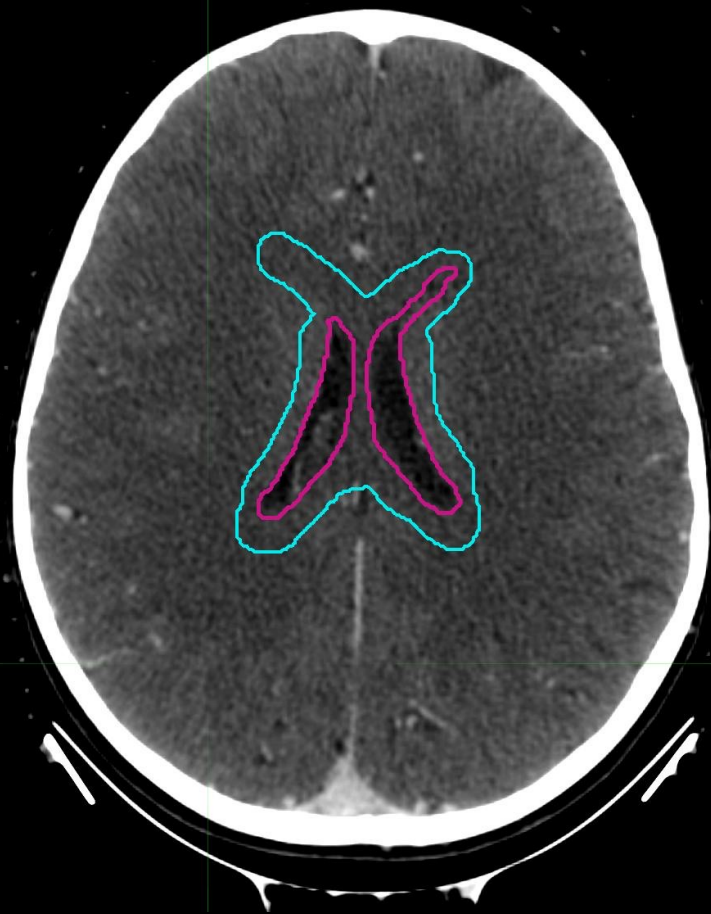■ WVVCTV  
■ WVPVTV



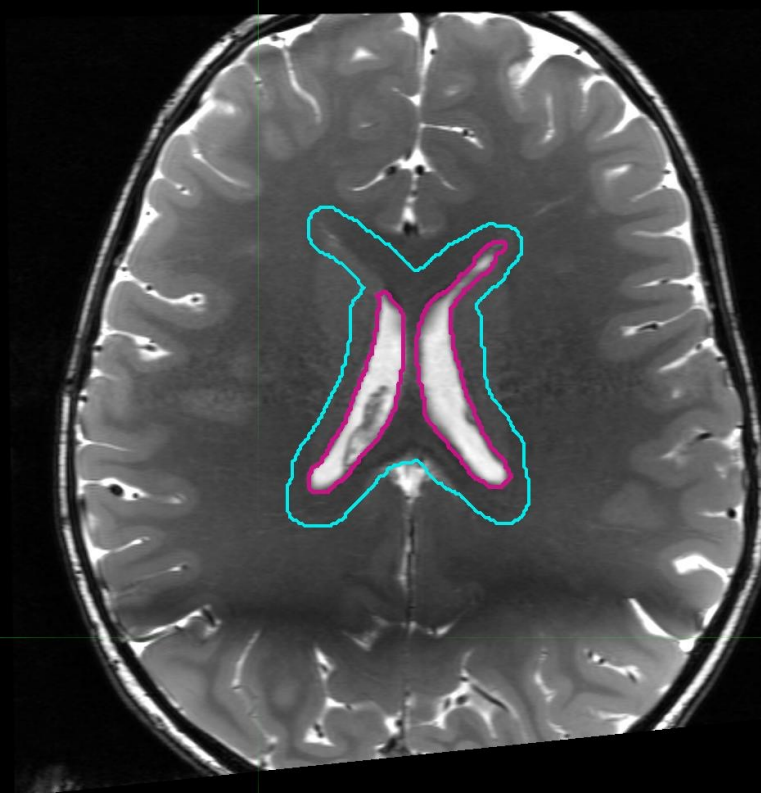
lateral ventricles

■ WVVCTV

■ WVVPTV

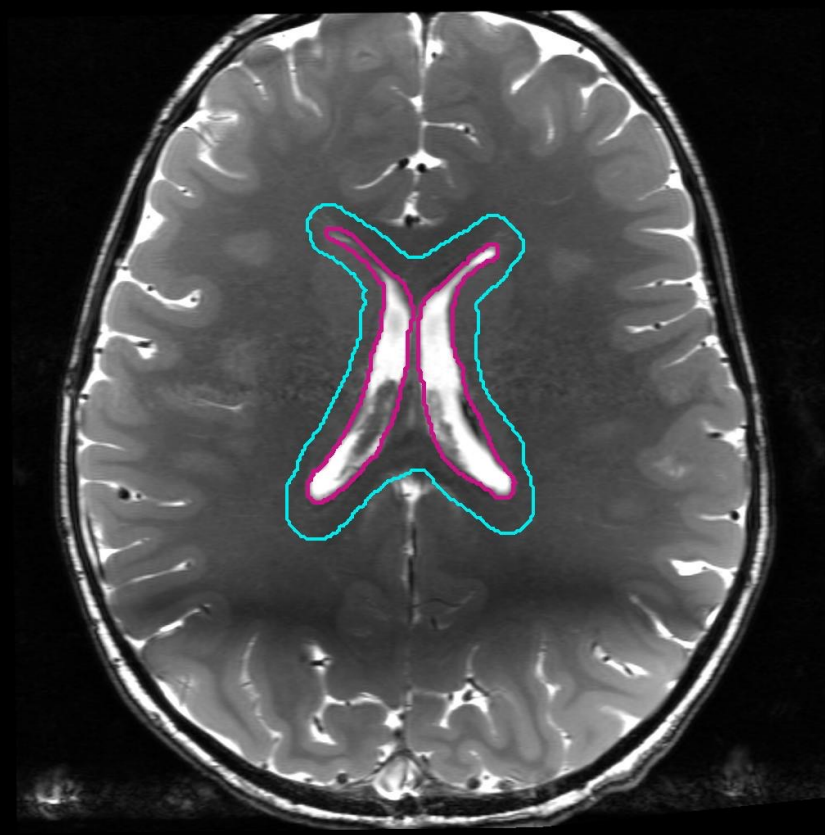
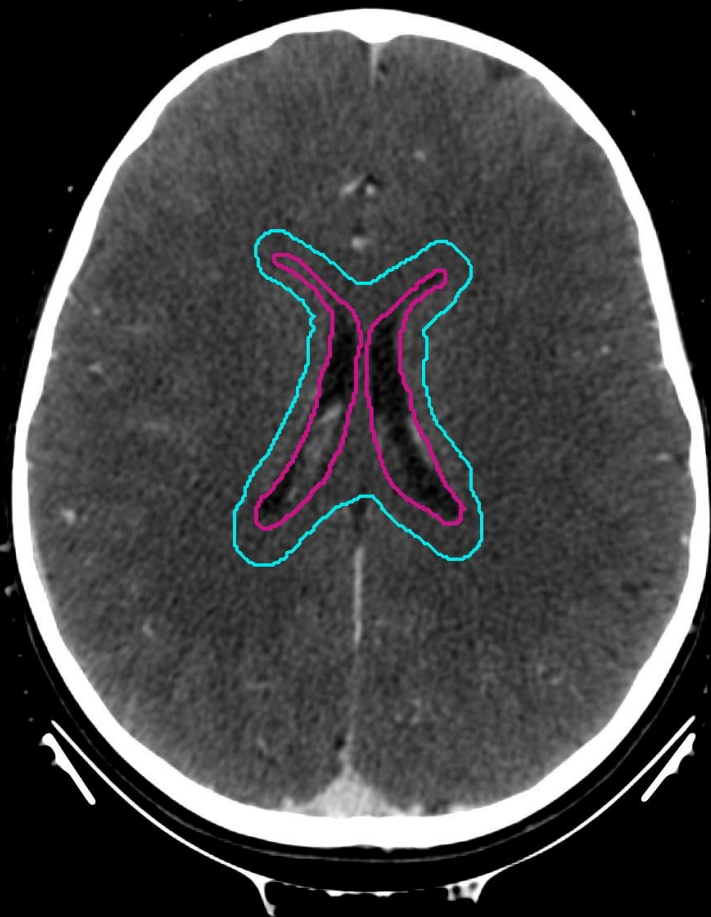

L R



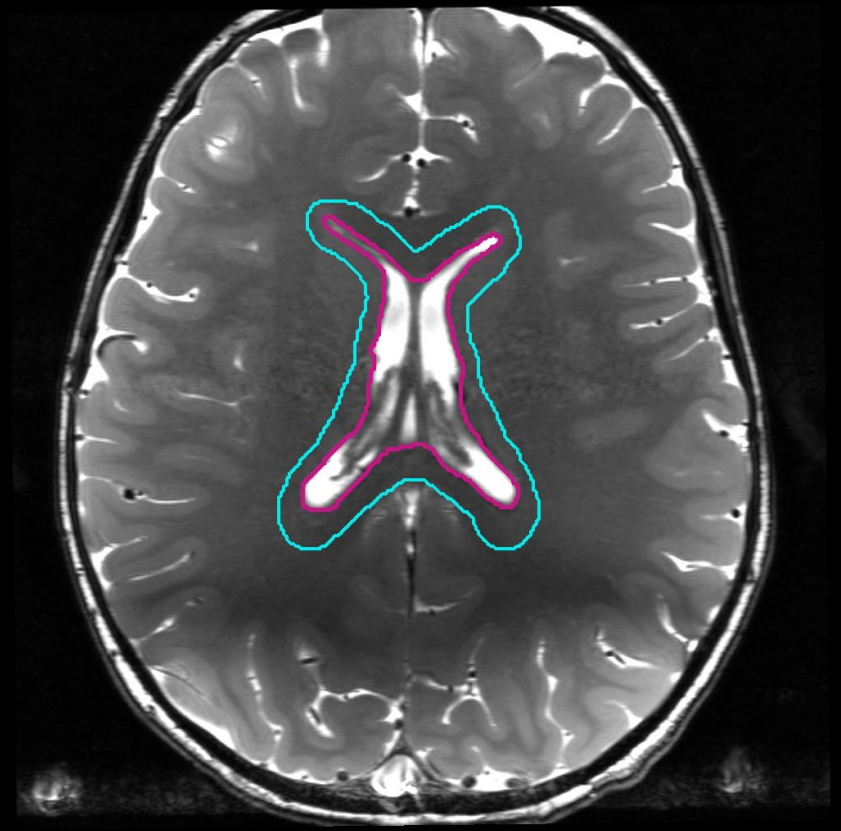
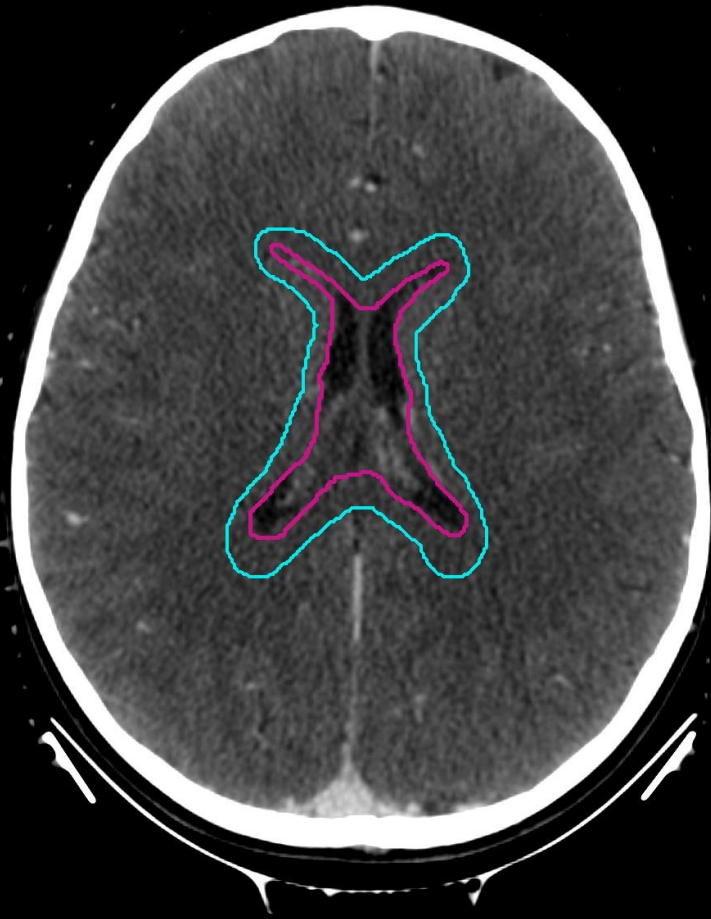■ WVVCTV

■ WVVPTV



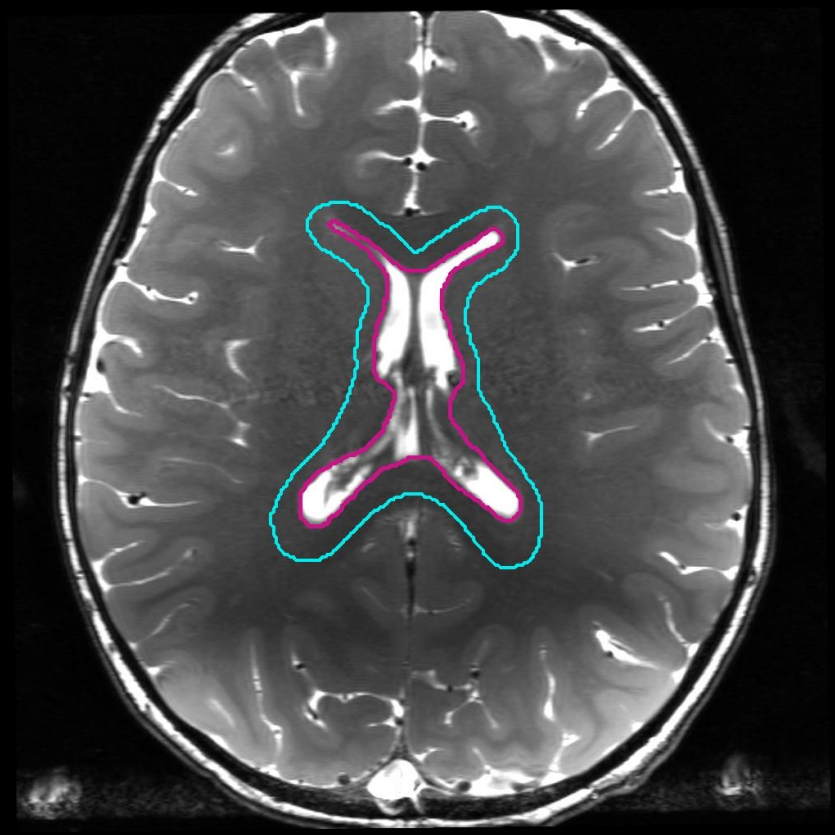
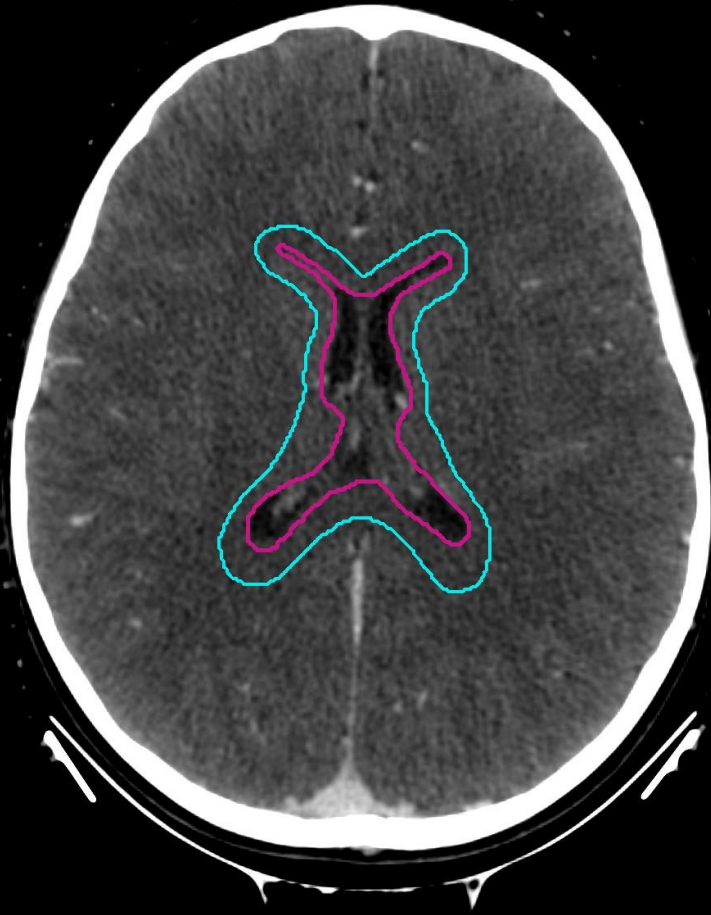■ WVVCTV

■ WVVPTV



■ WVVCTV

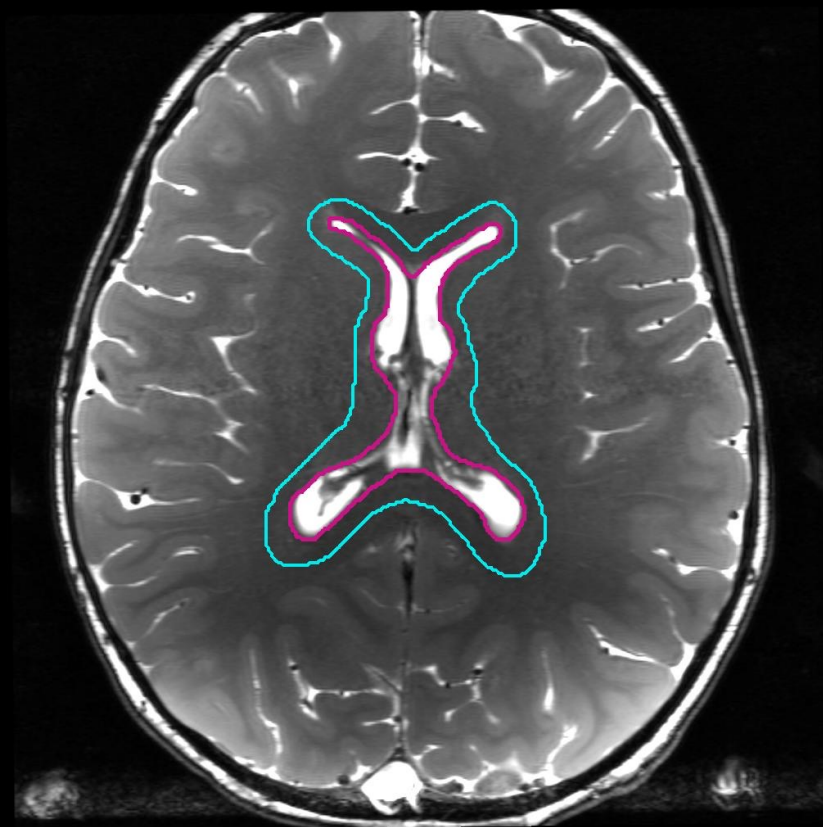
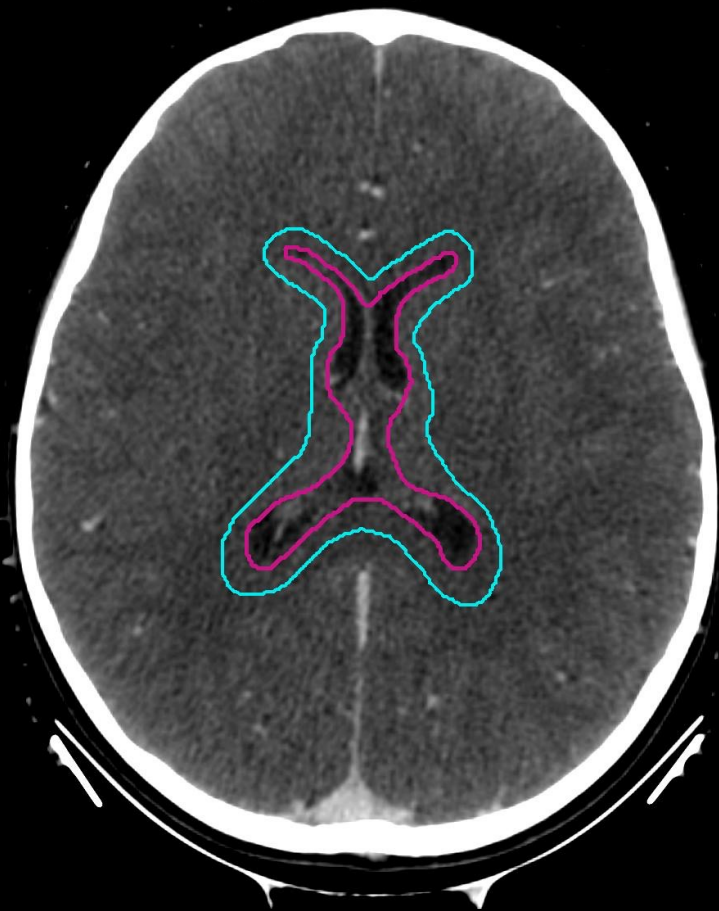■ WVVPTV



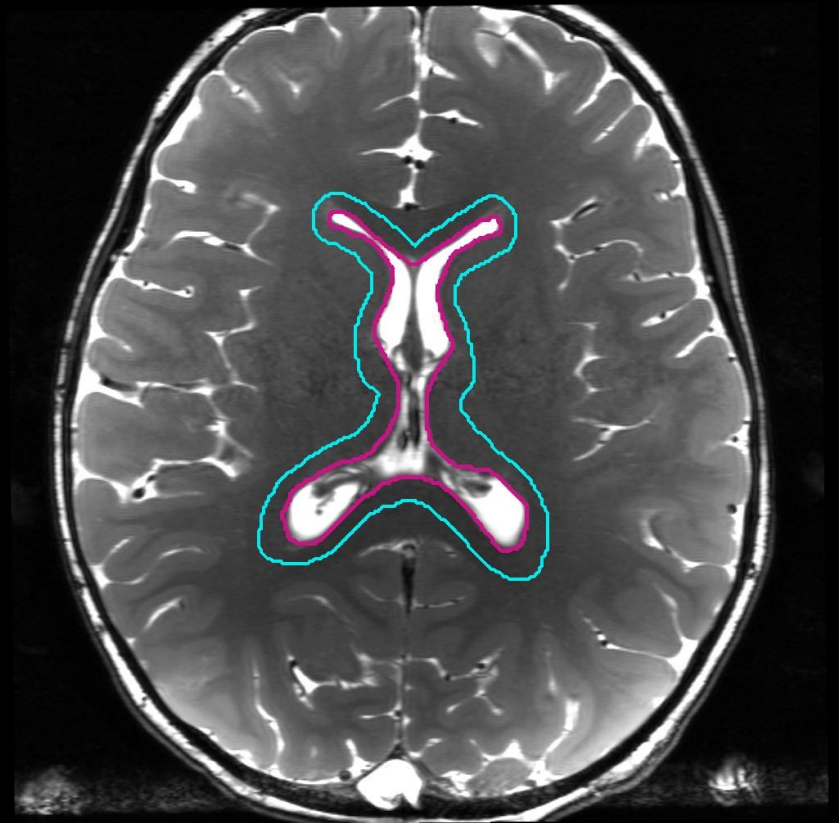
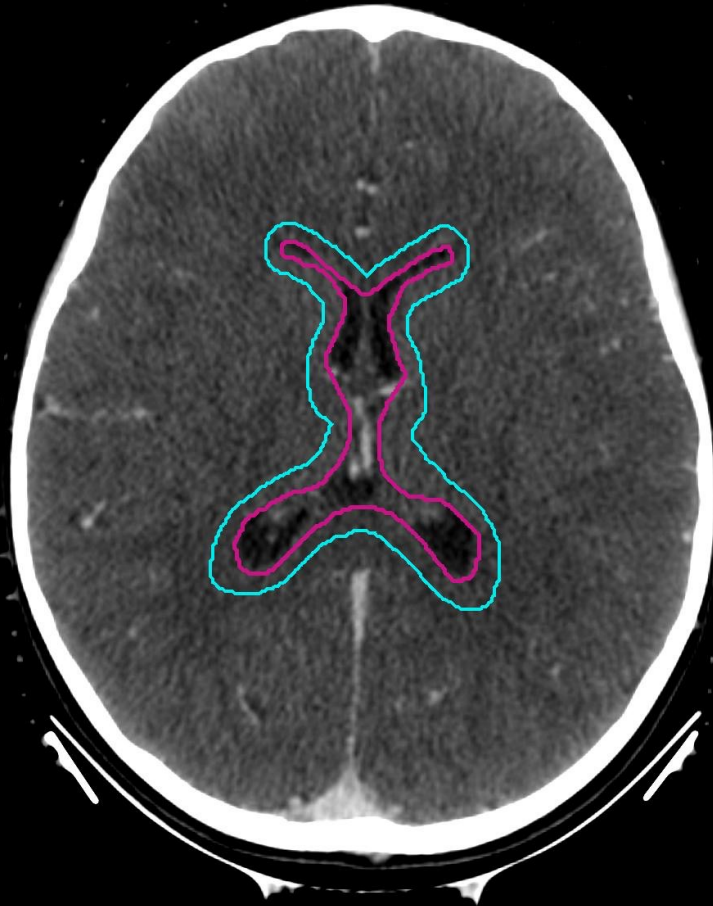

■ WVVCTV

■ WVVPTV



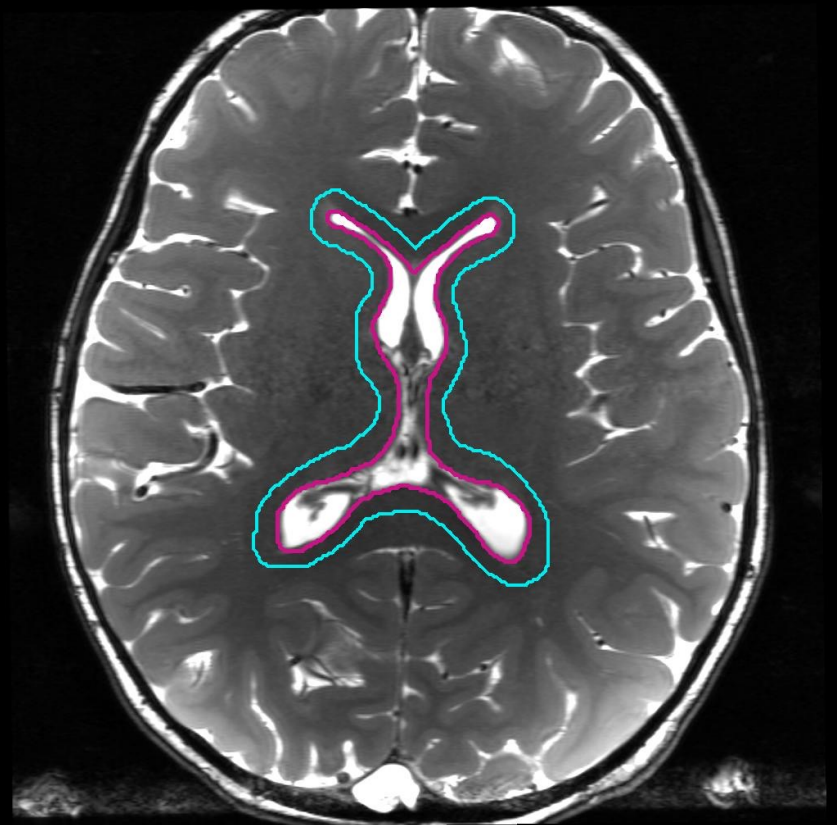
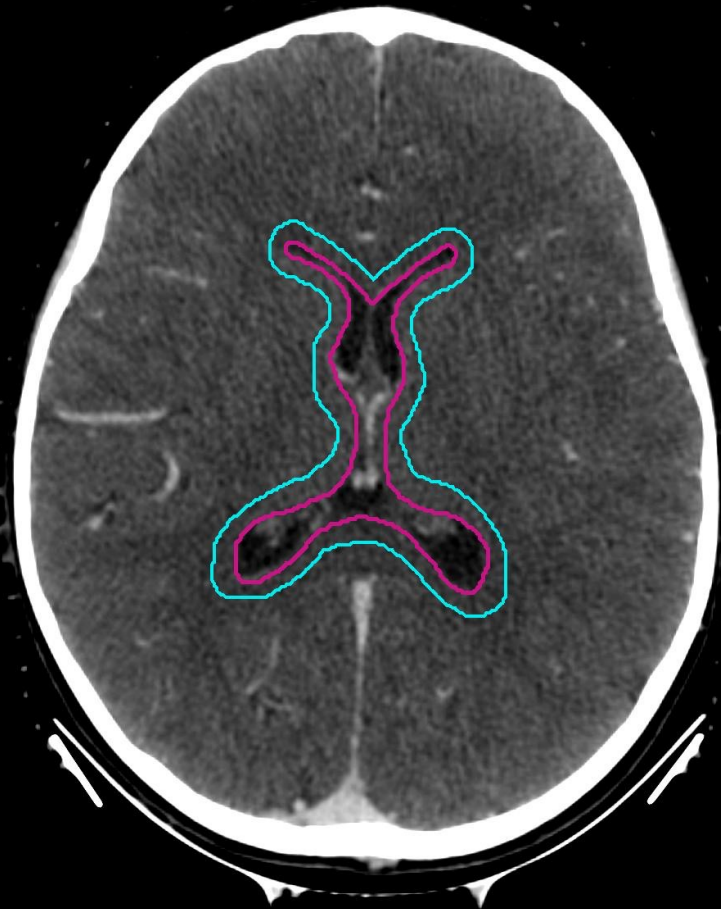■ WVVCTV  
■ WVVPTV



anterior horn of lateral ventricles

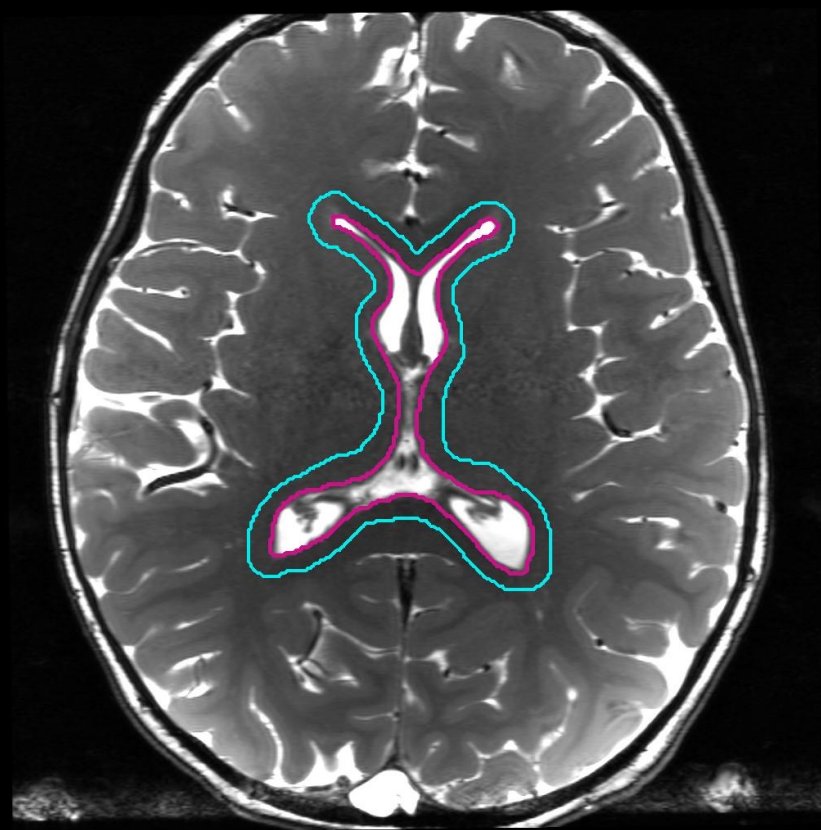
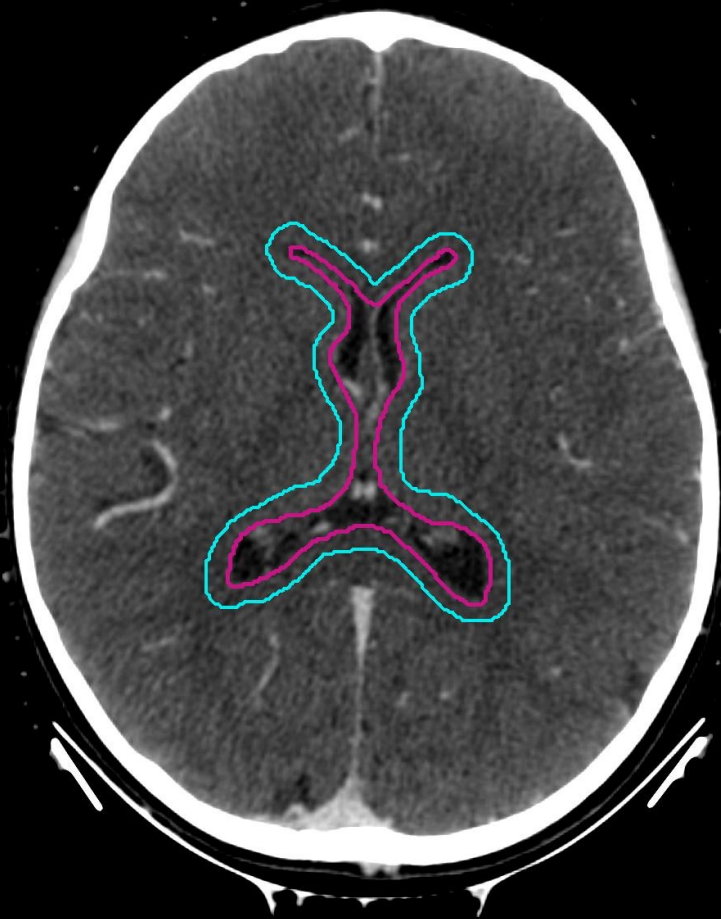■ WVVCTV

■ WVVPTV



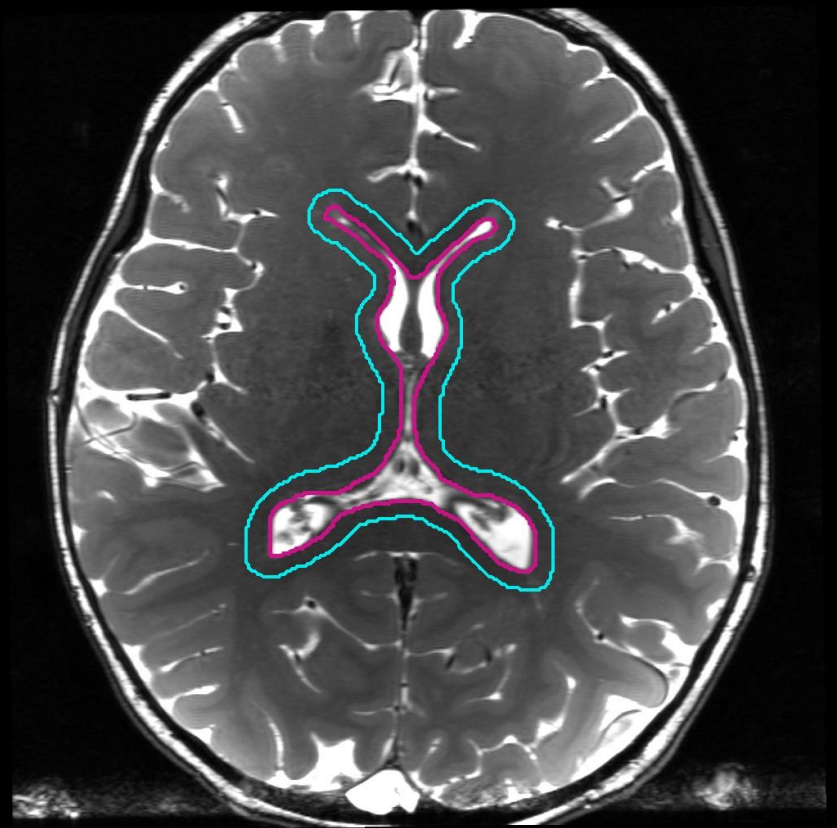
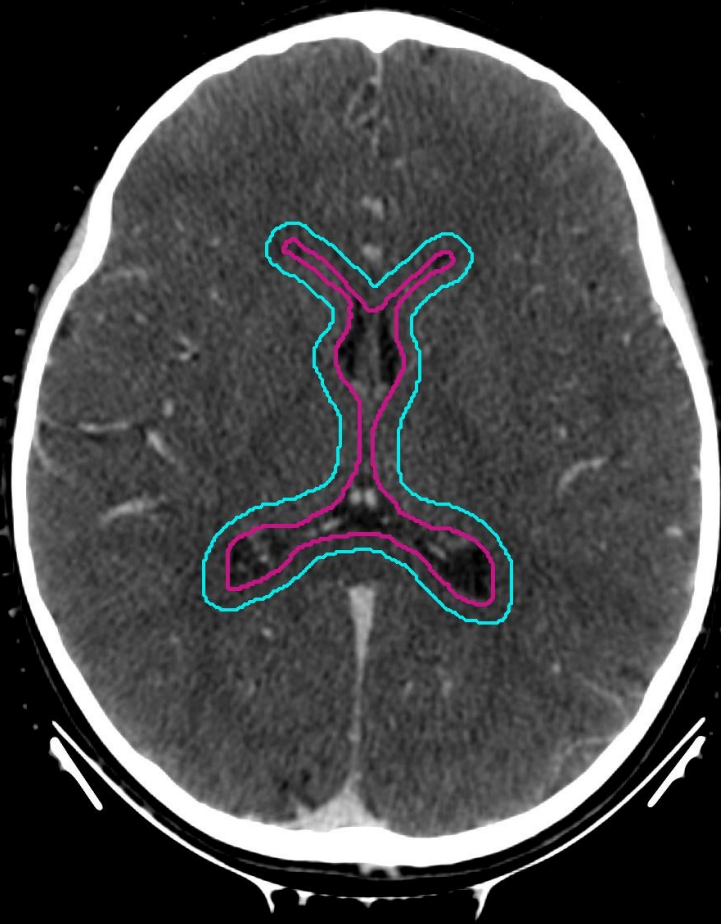■ WVVCTV

■ WVPPTV



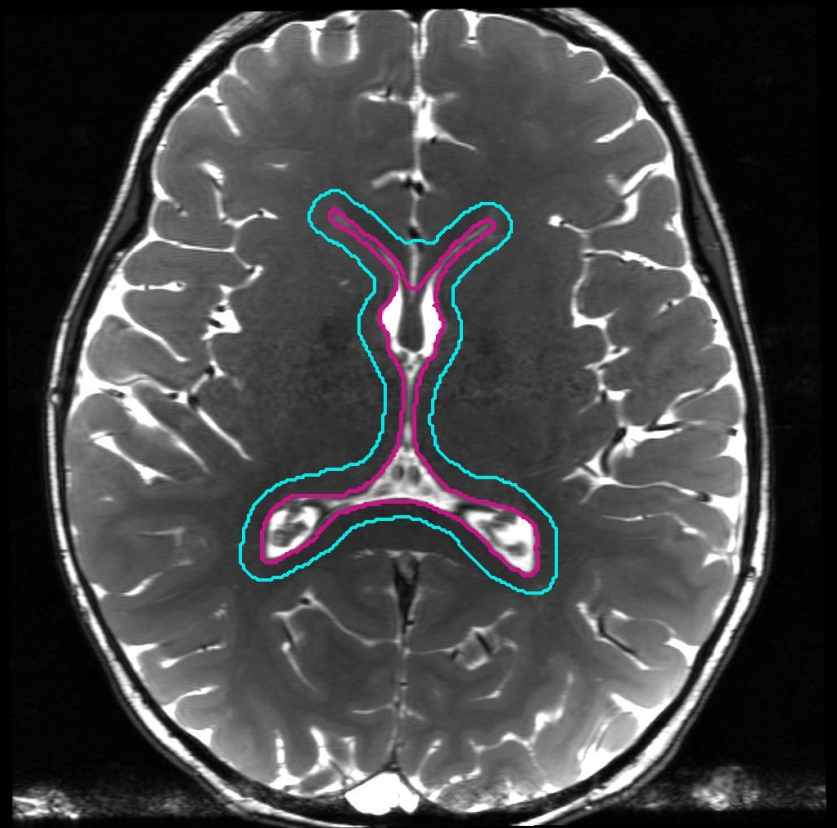
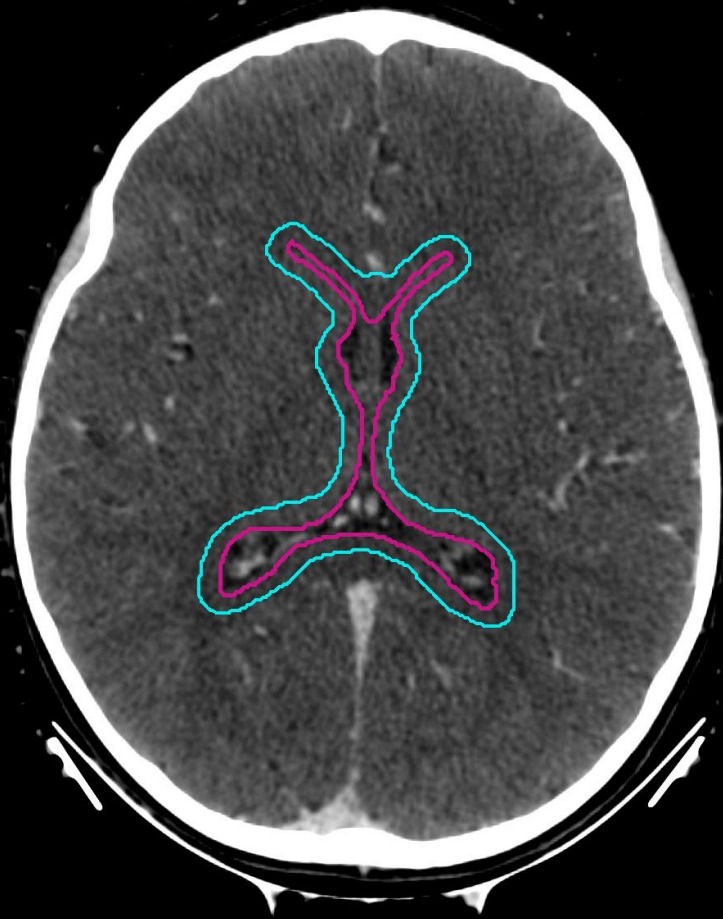
■ WVVCTV

■ WVVPTV



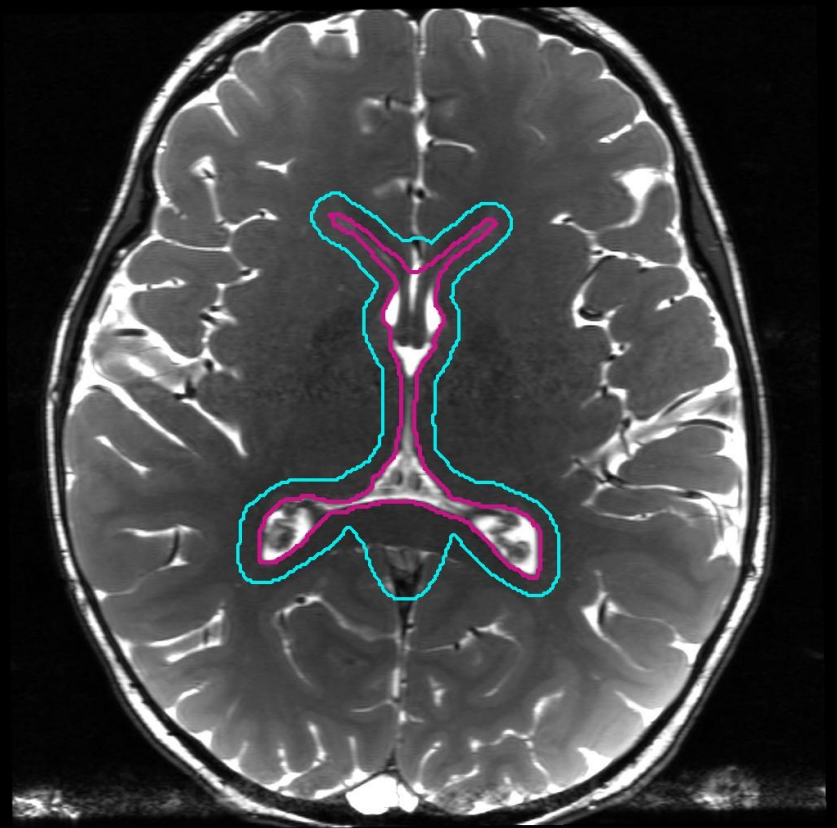
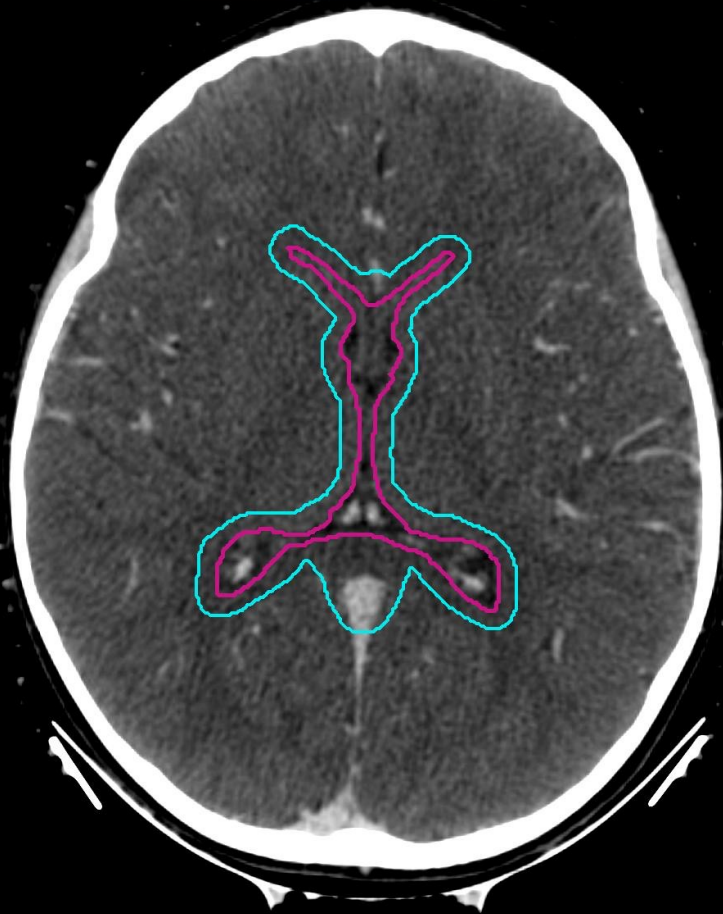■ WVVCTV

■ WVVPTV



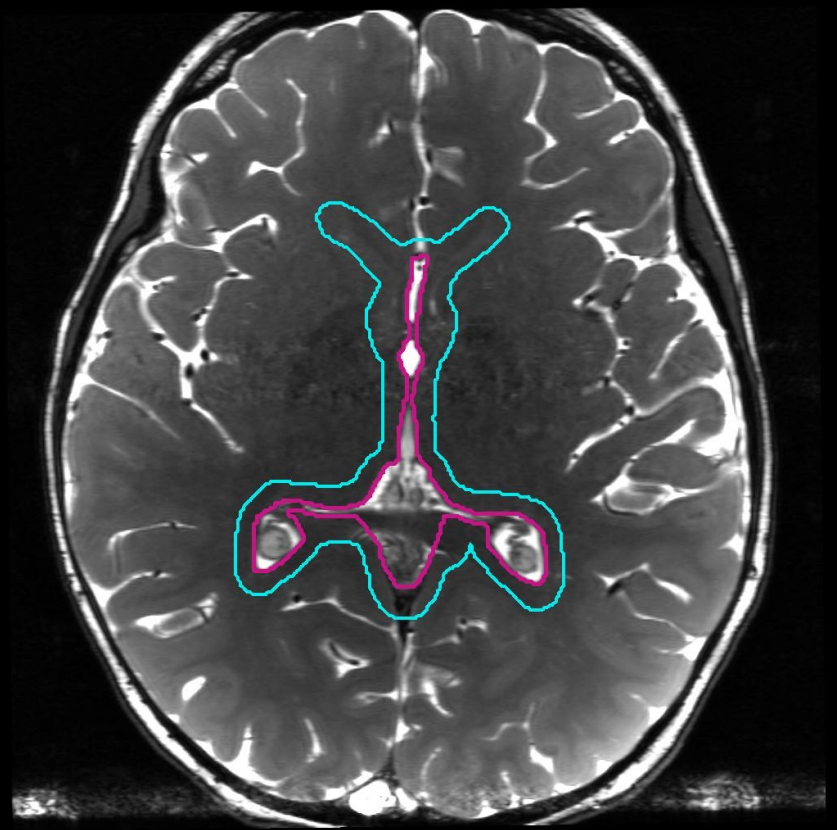
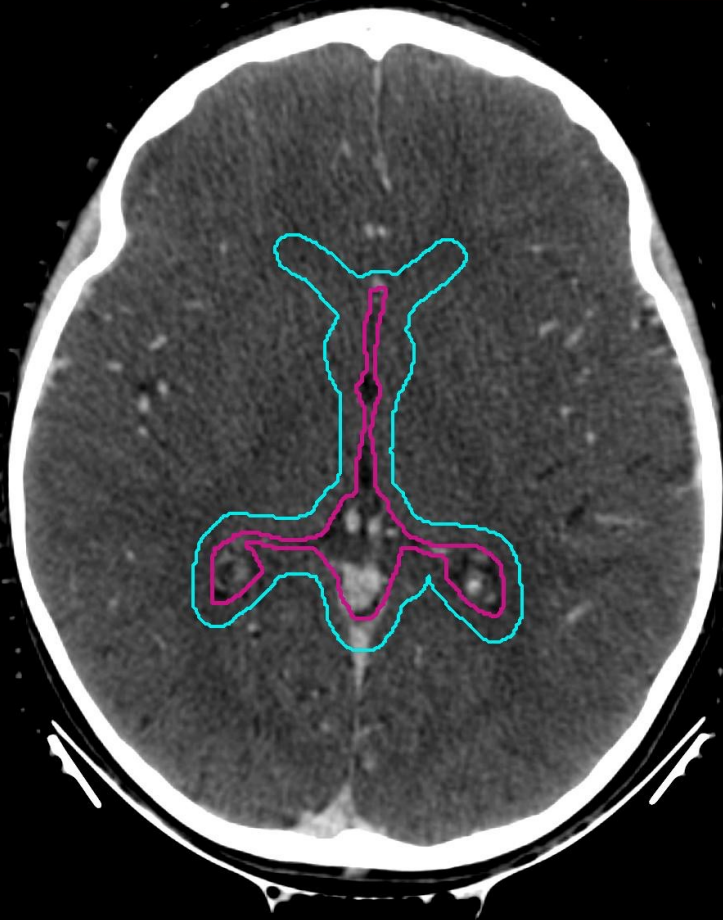
■ WVVCTV

■ WVPVTV



■ WVVCTV

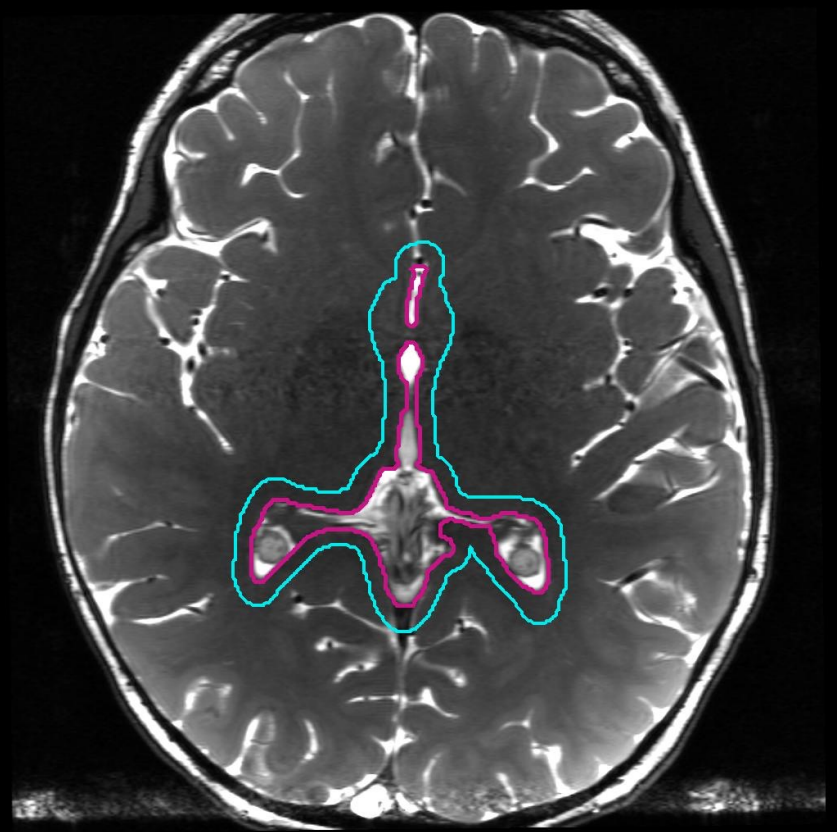
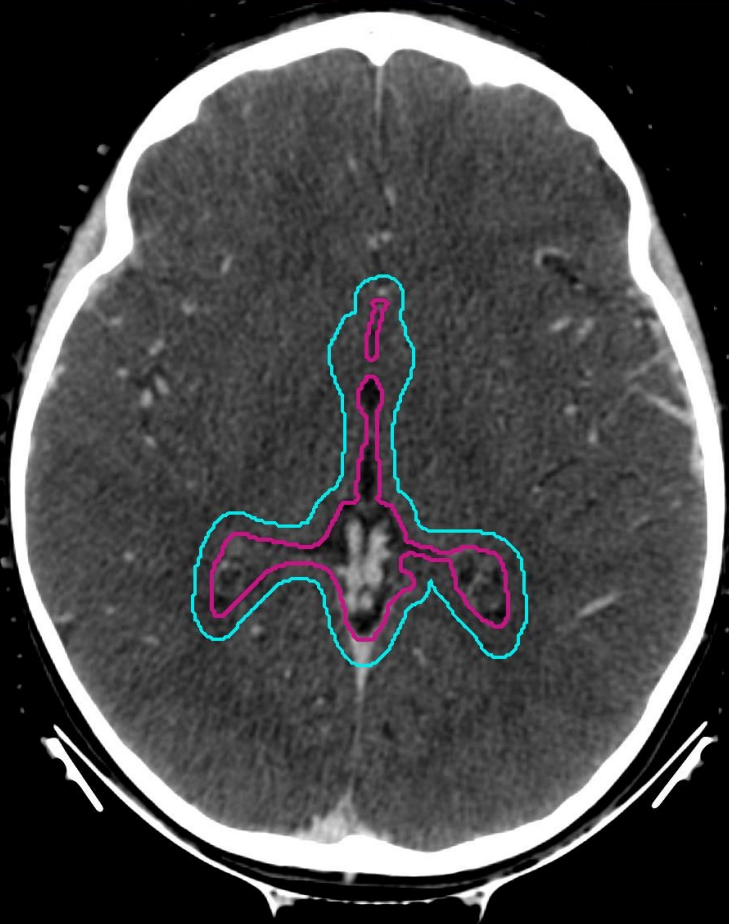■ WVVPTV





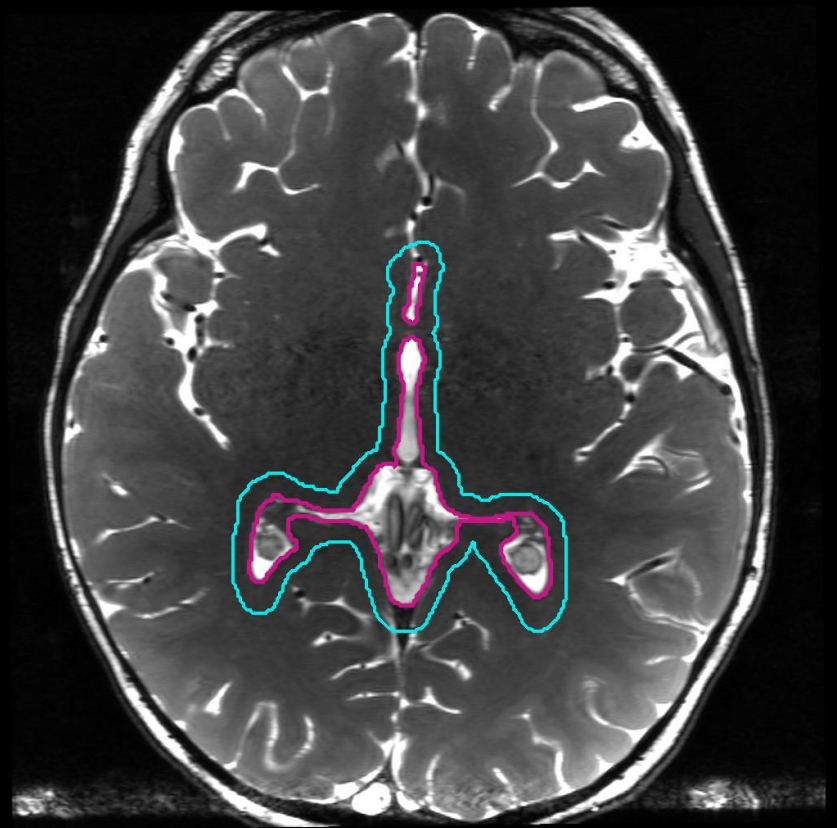
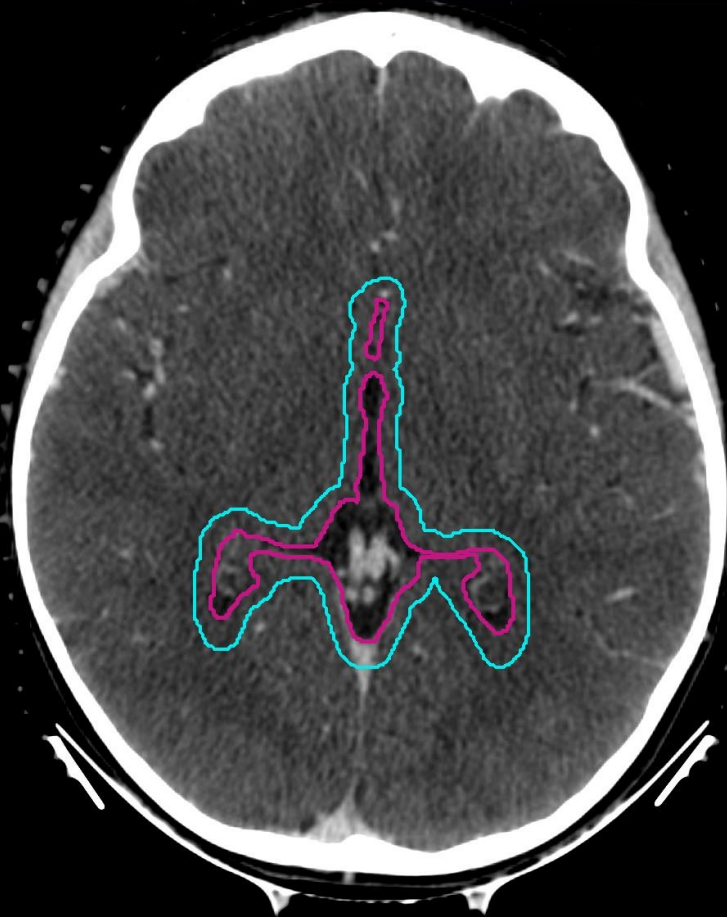
■ WVVCTV

■ WVVPTV

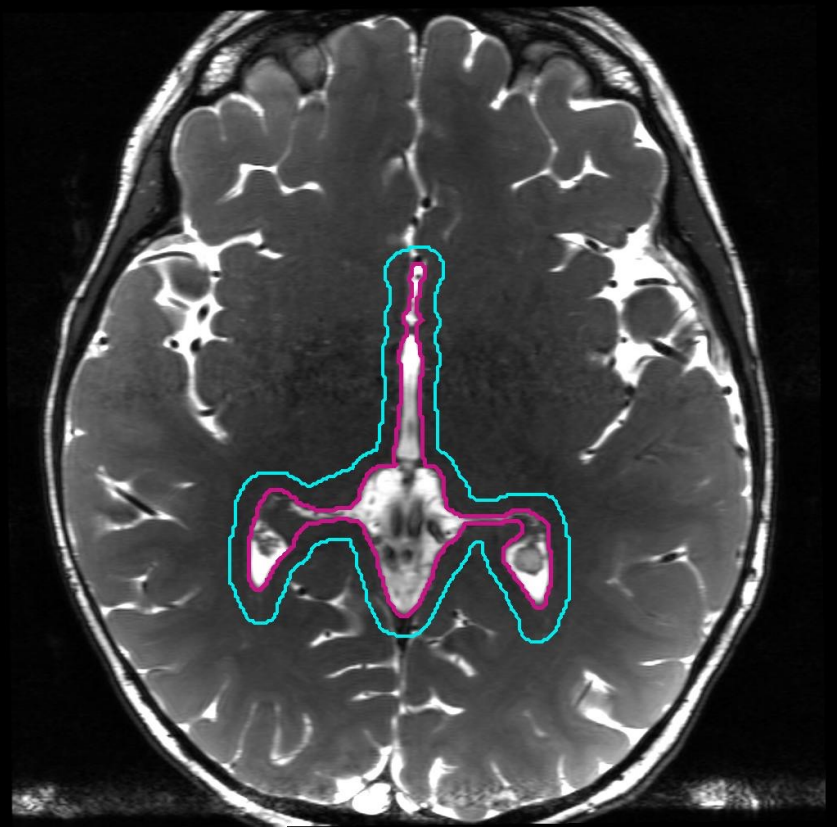
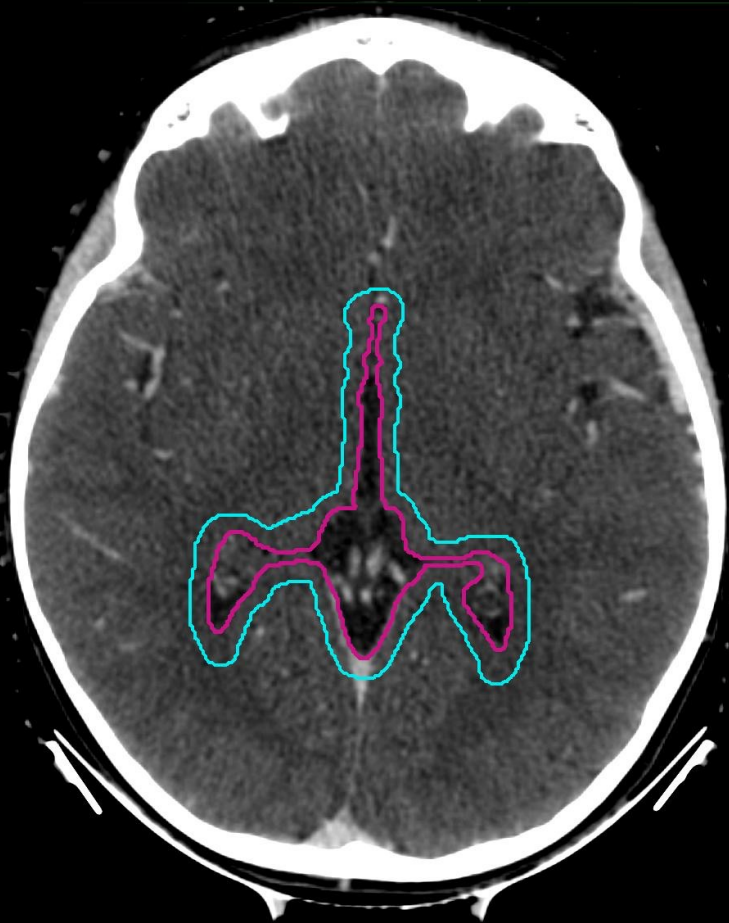


■ WVVCTV

■ WVVPTV



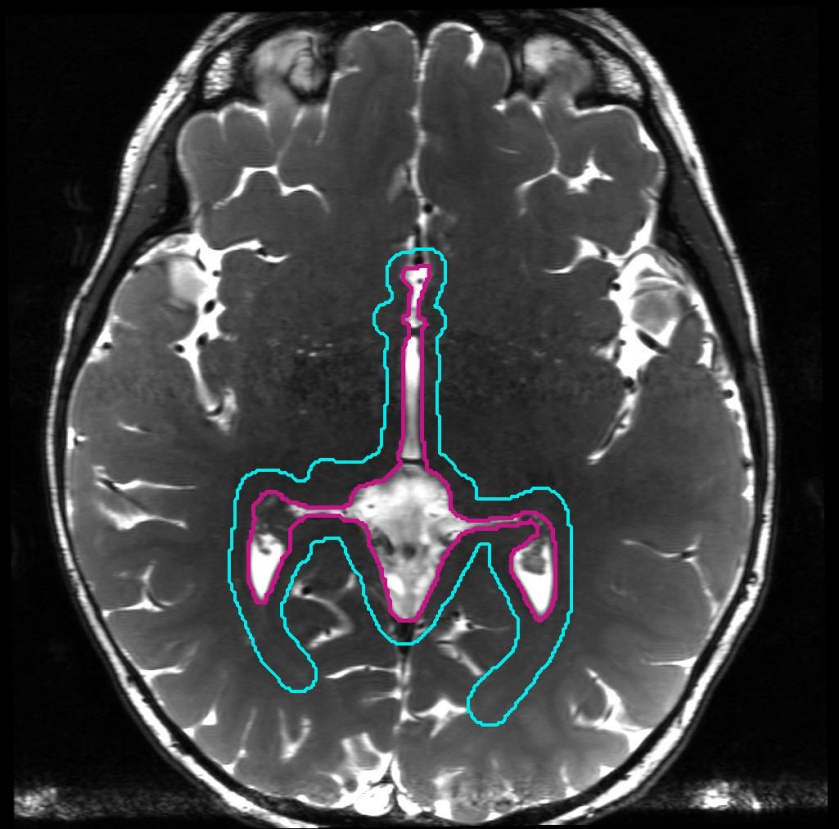
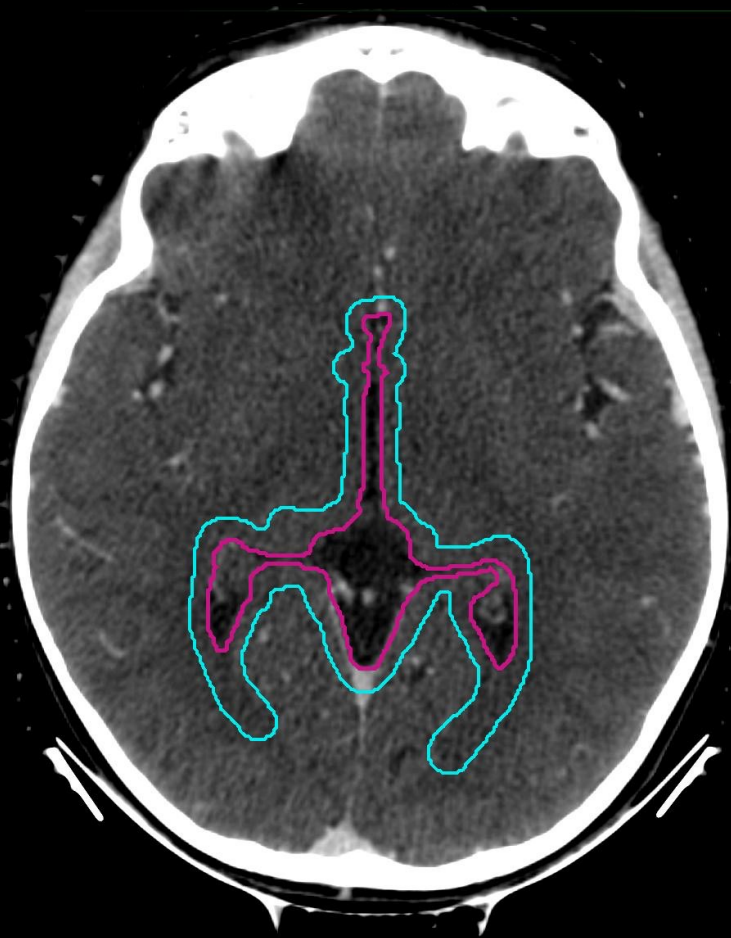■ WVVCTV  
■ WVVPTV



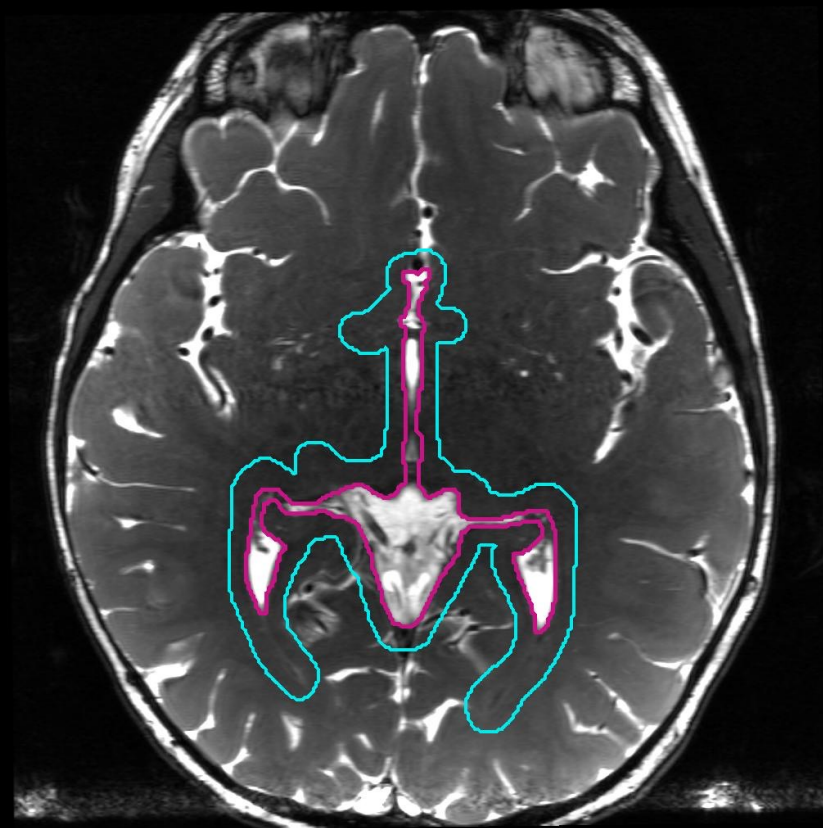
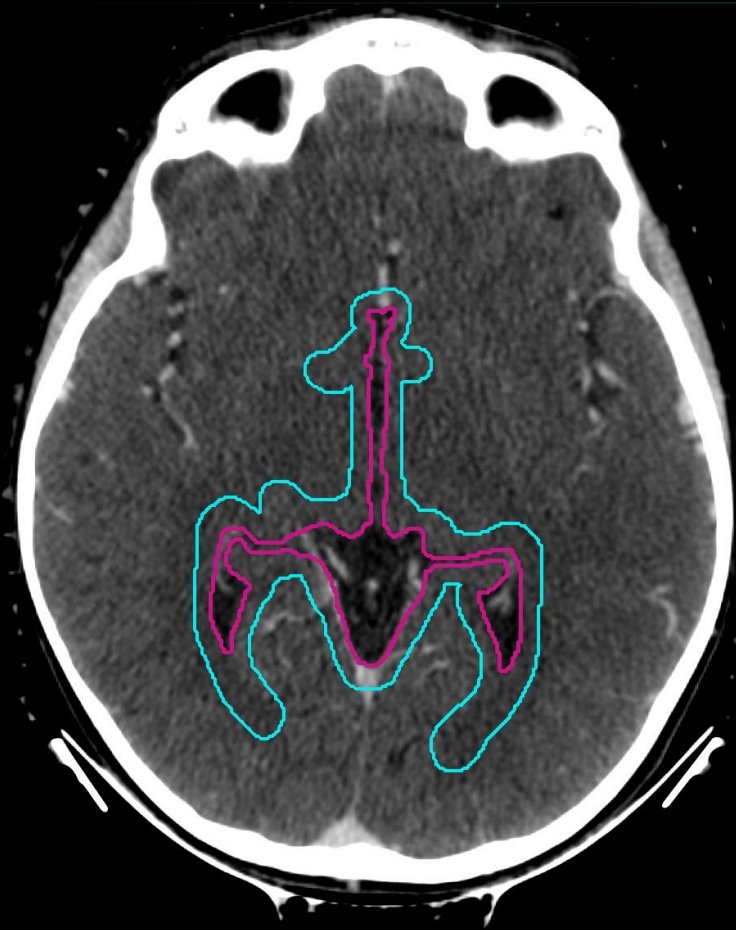third ventricle, region of pineal cistern

■ WVVCTV

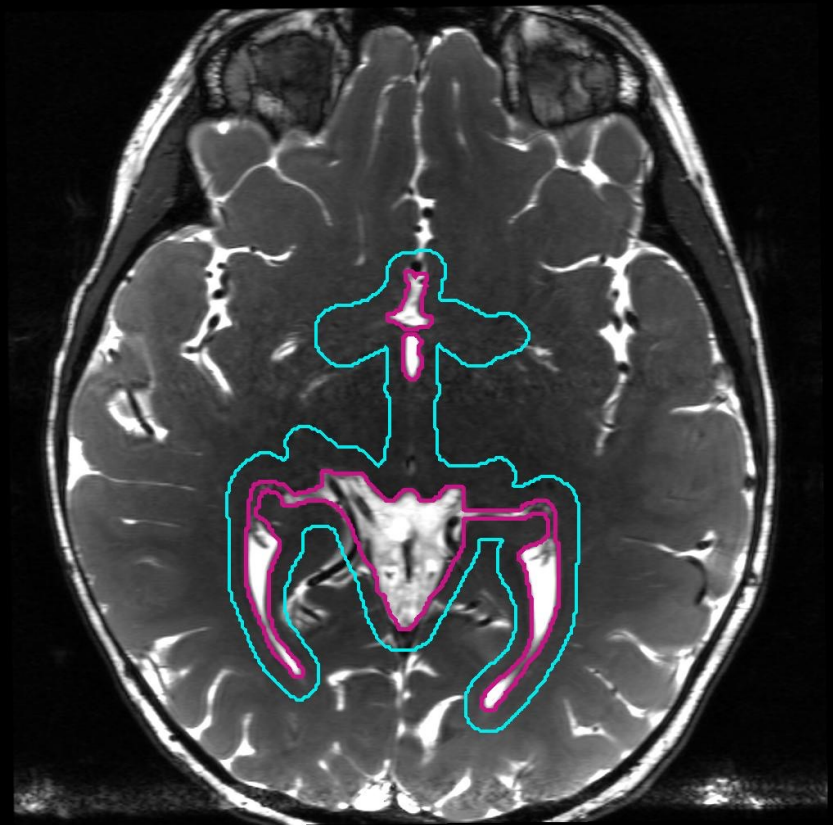
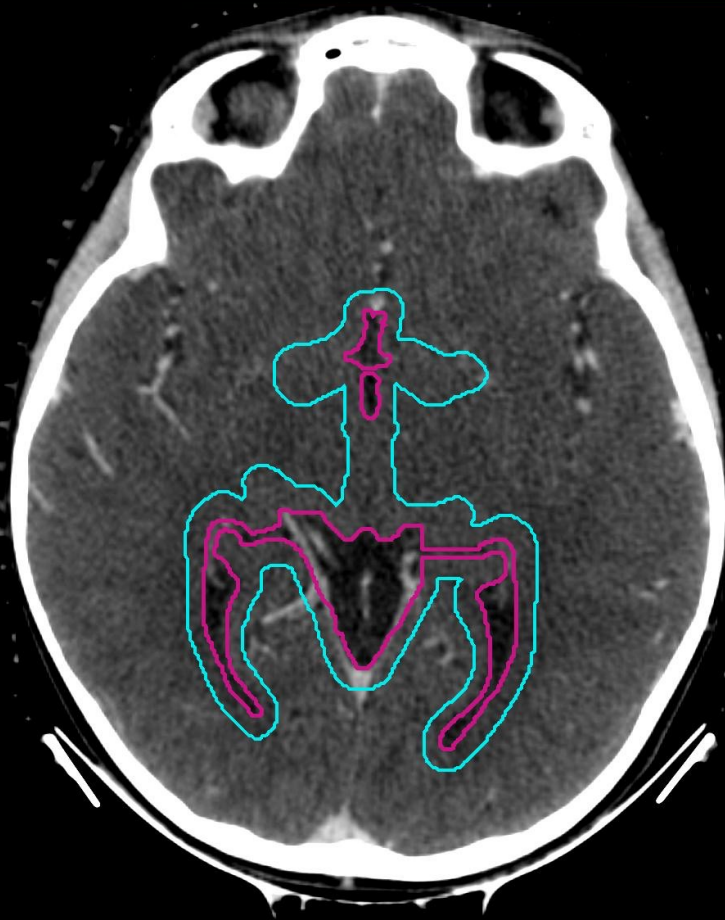
■ WVVPTV



■ WVVCTV  
■ WVPPTV



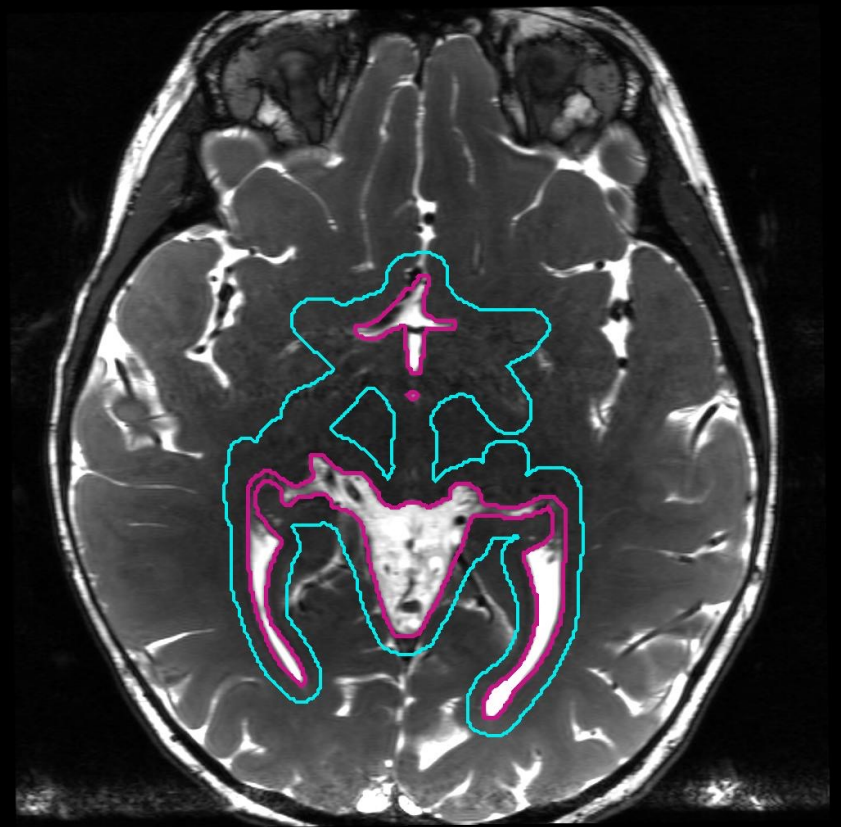
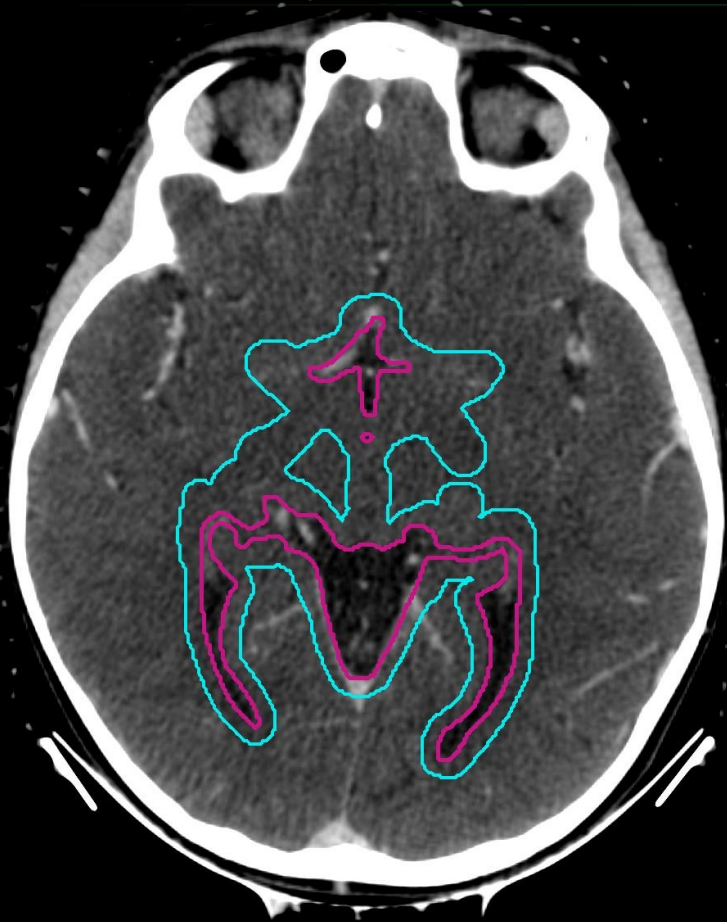■ WVVCTV  
■ WVVPTV



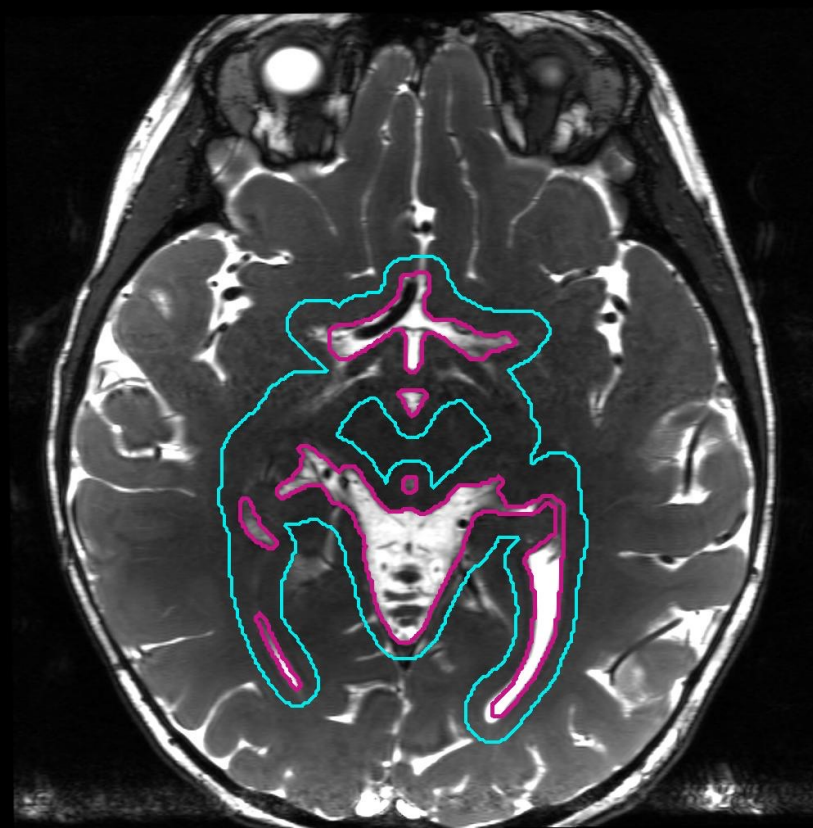
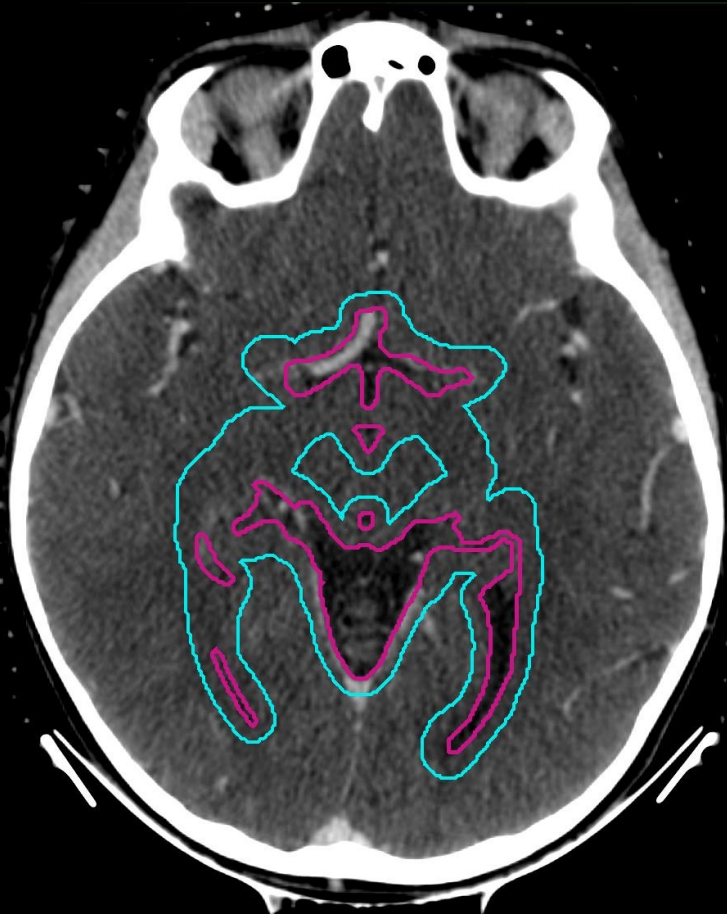
third ventricle, region of pineal cistern  
occipital horns of lateral ventricles

■ WVVCTV

■ WVPPTV



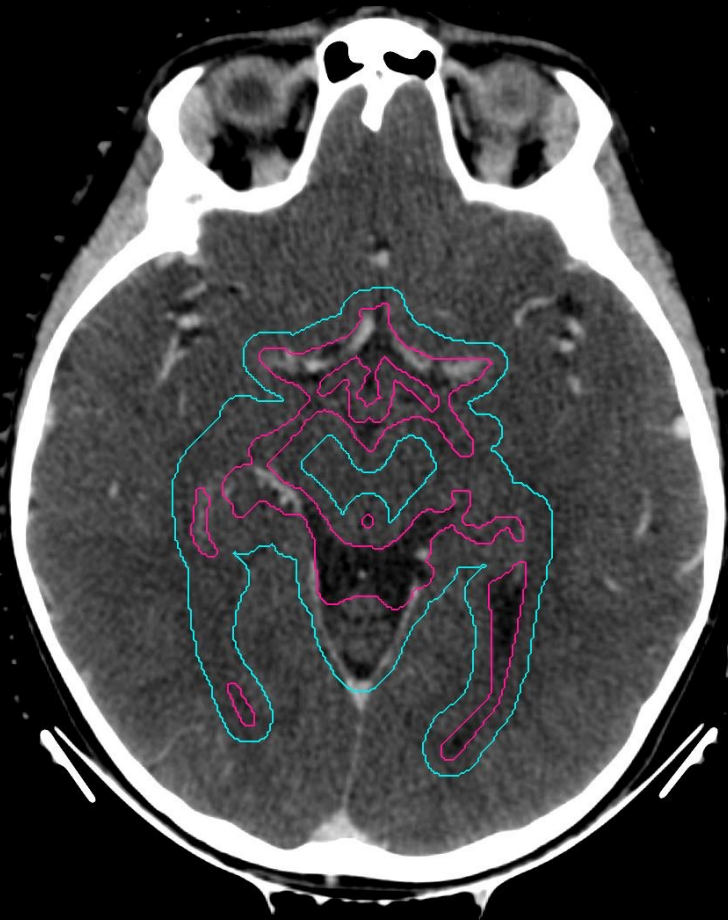■ WVVCTV  
■ WVVPTV





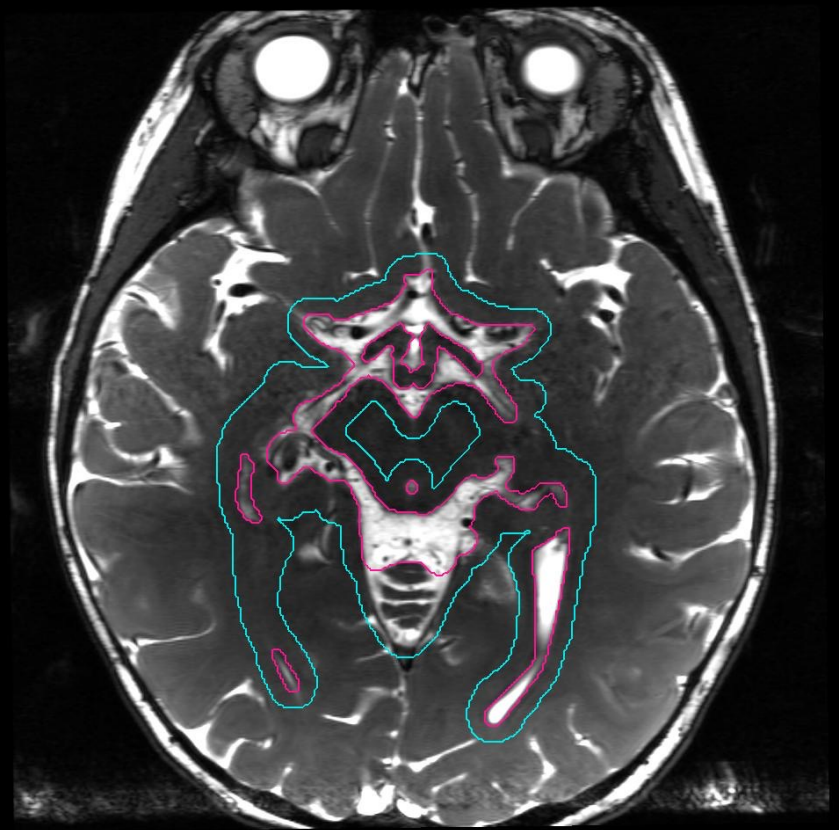
■ WVVCTV

■ WVVPTV



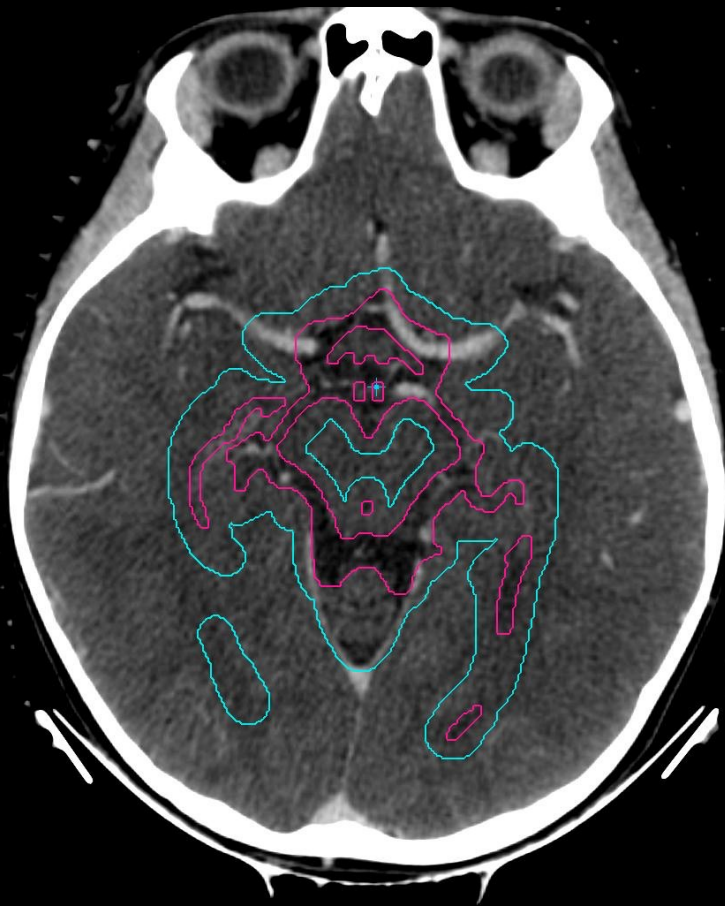
L

R

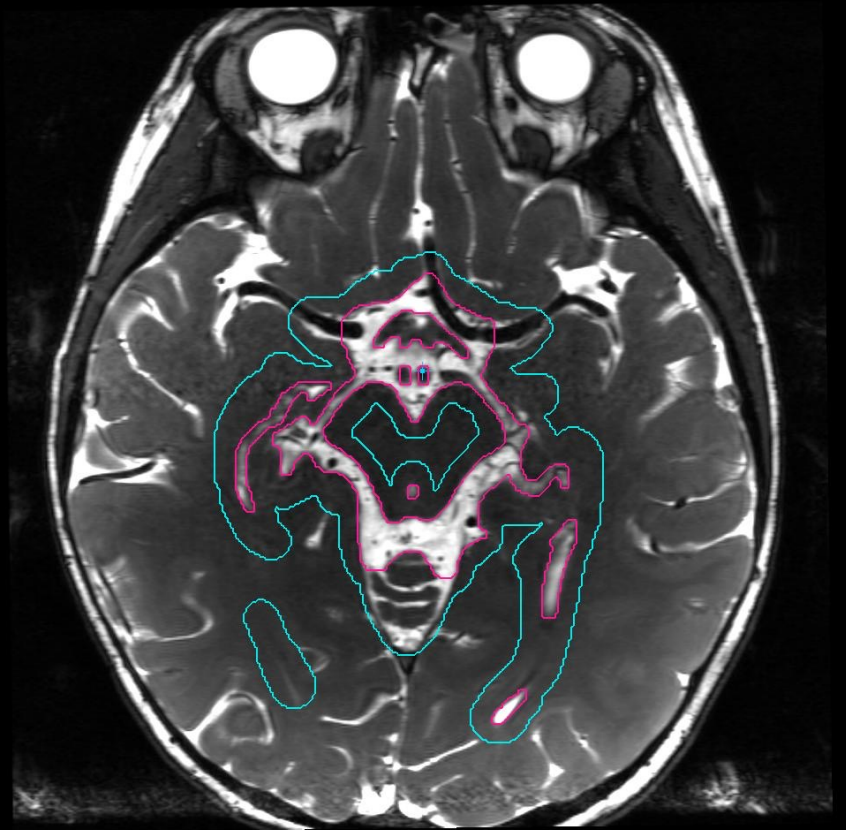


■ WVVCTV

■ WVVPTV

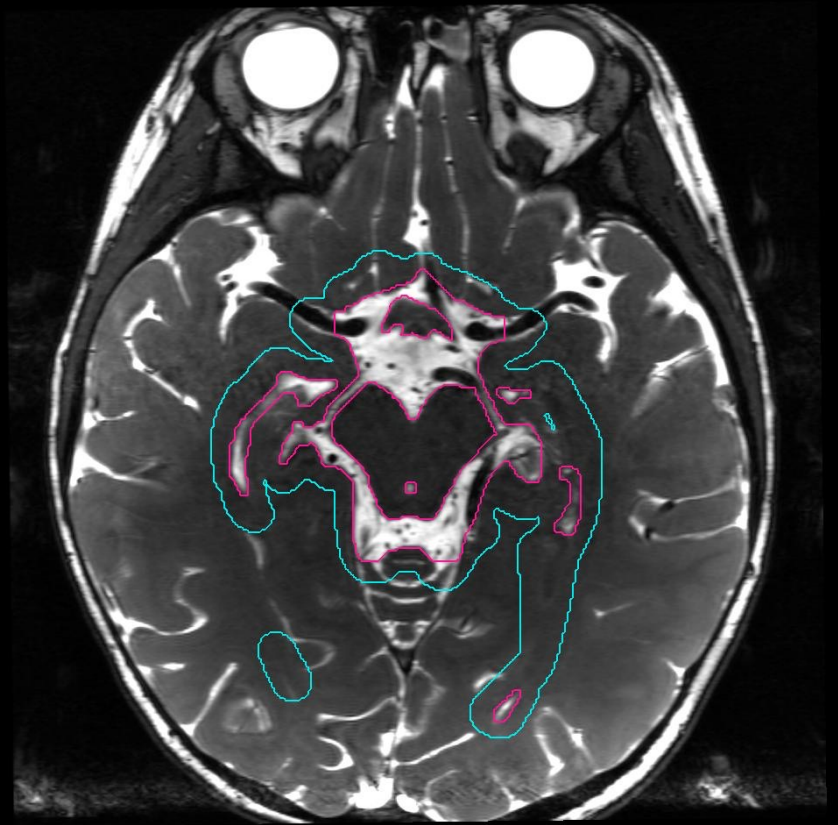
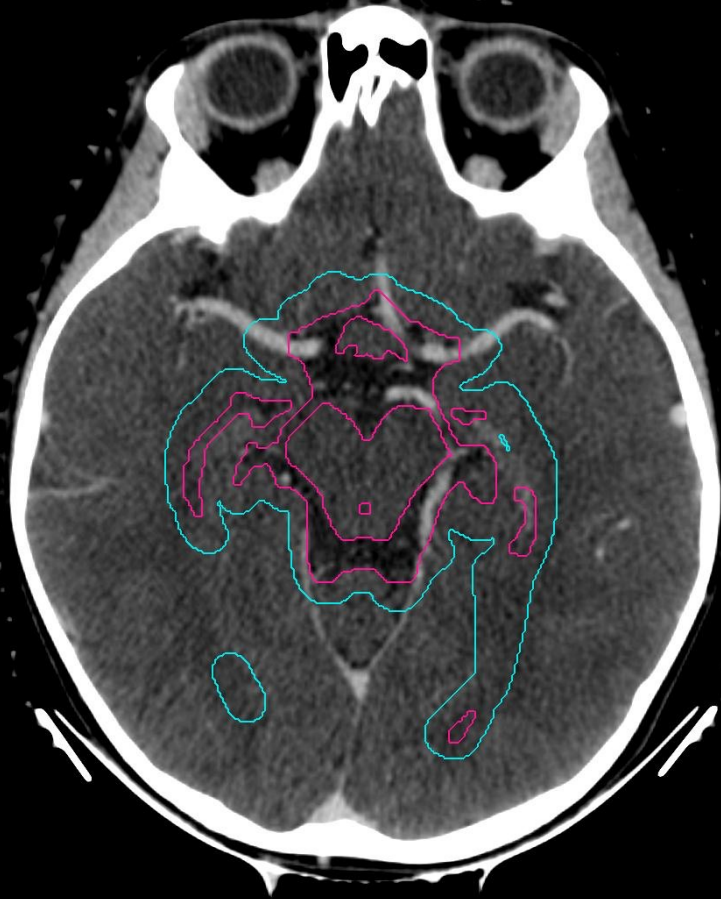

L R



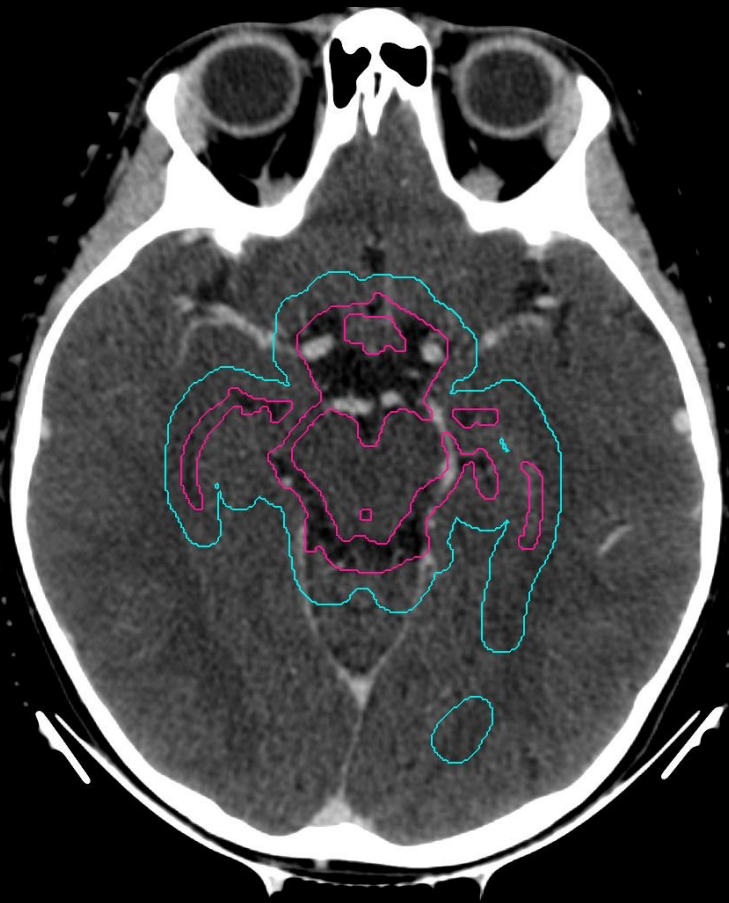
■ WVVCTV

■ WVVPTV

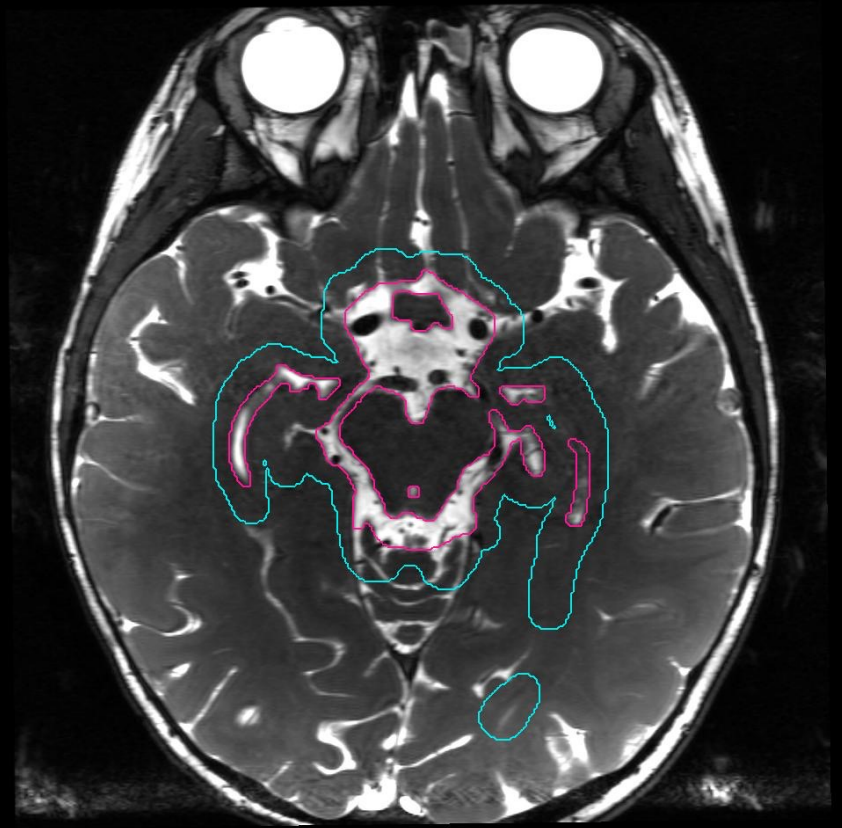


■ WVVCTV

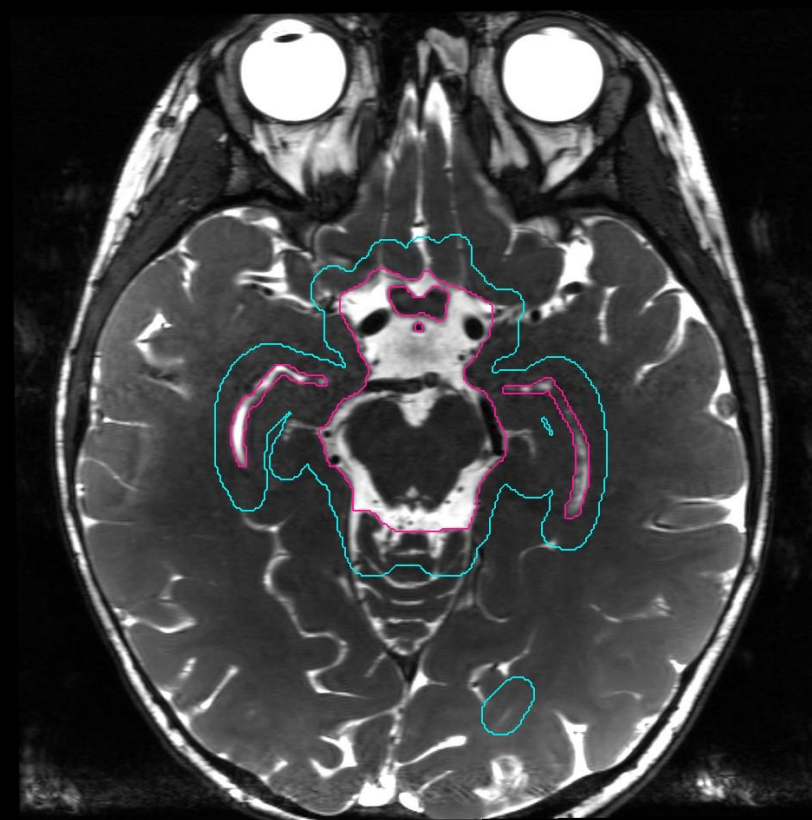
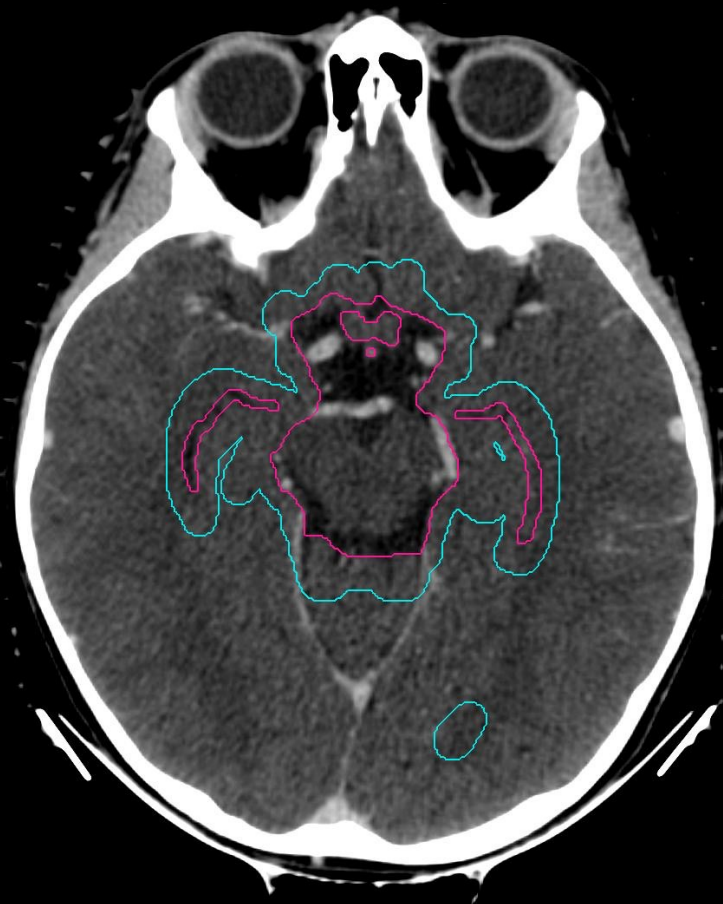
■ WVVPTV



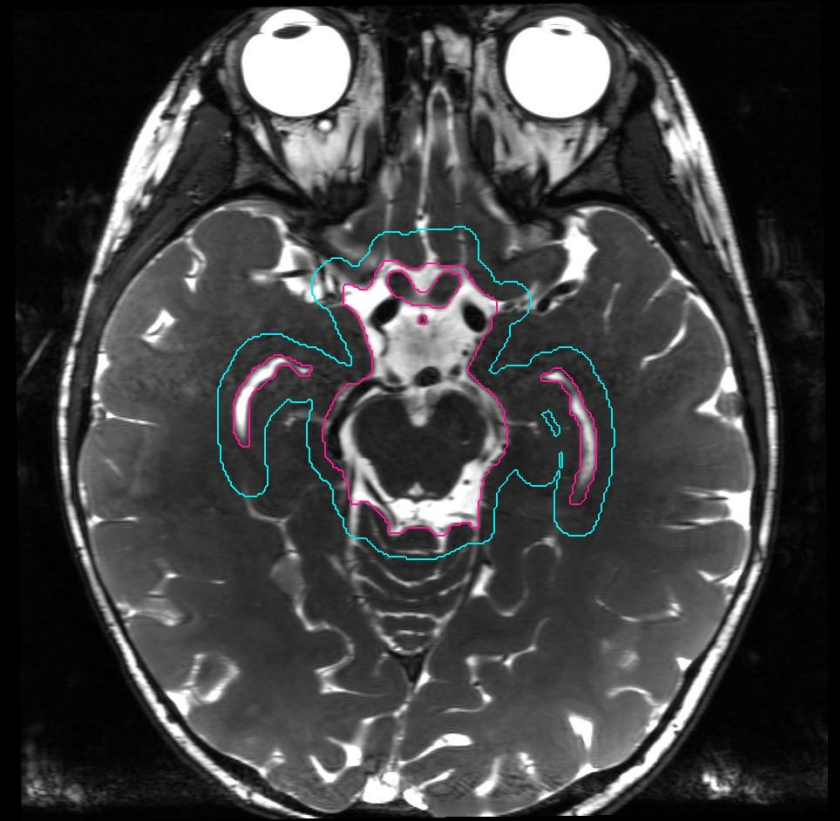
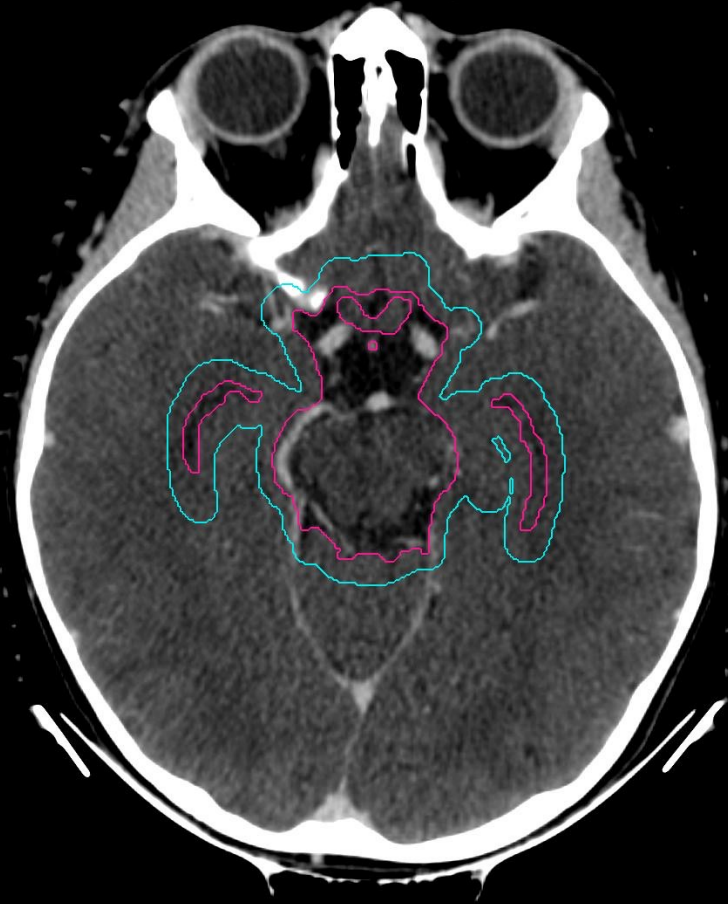L R



■ WVVCTV  
■ WVVPTV



■ WVVCTV  
■ WVVPTV

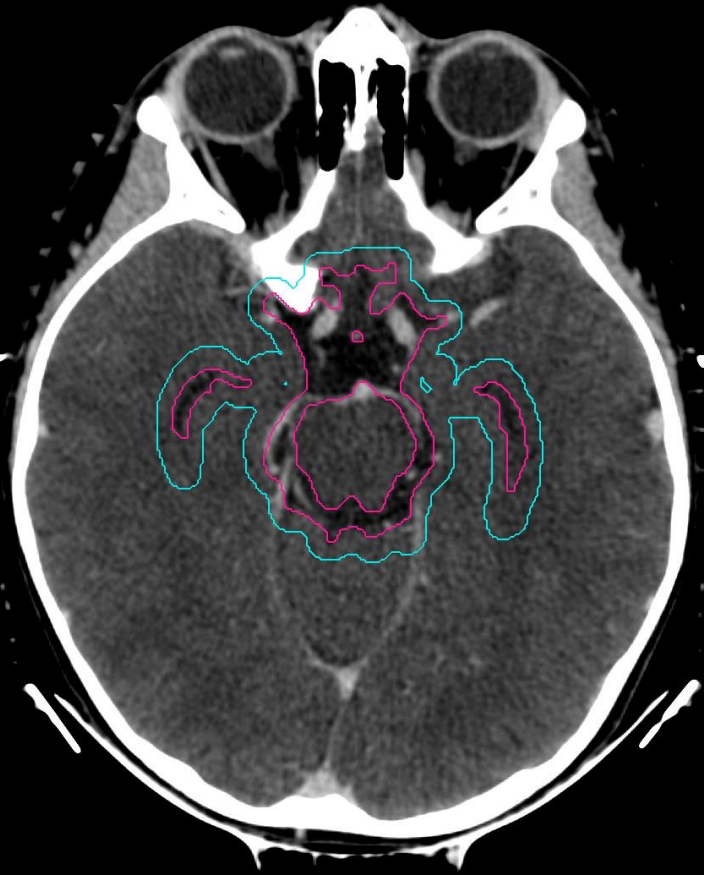

L R

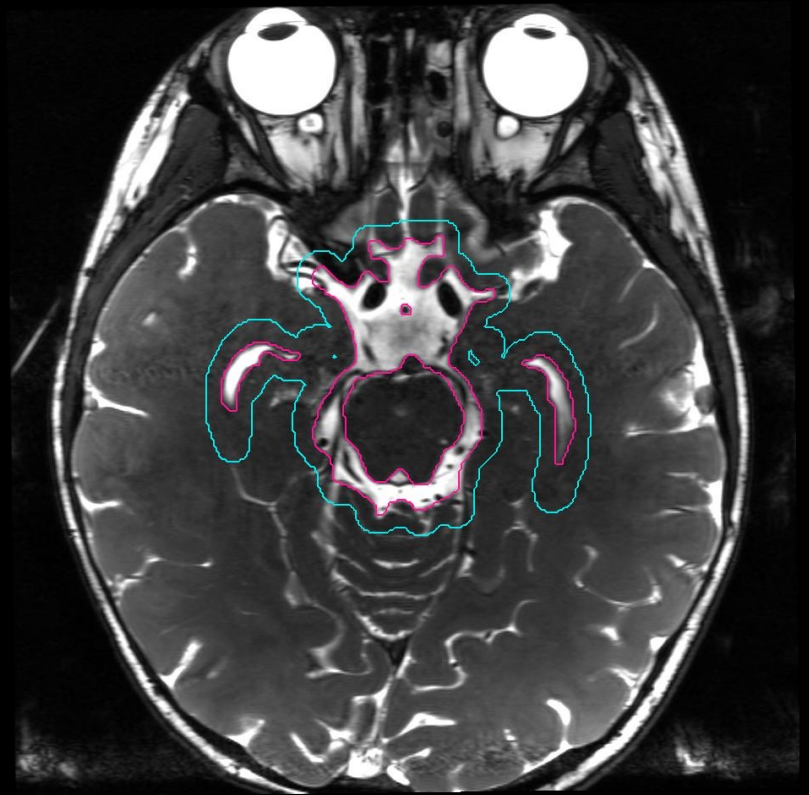
region of suprasellar cistern  
temporal horns of lateral ventricles

■ WVVCTV

■ WVVPTV

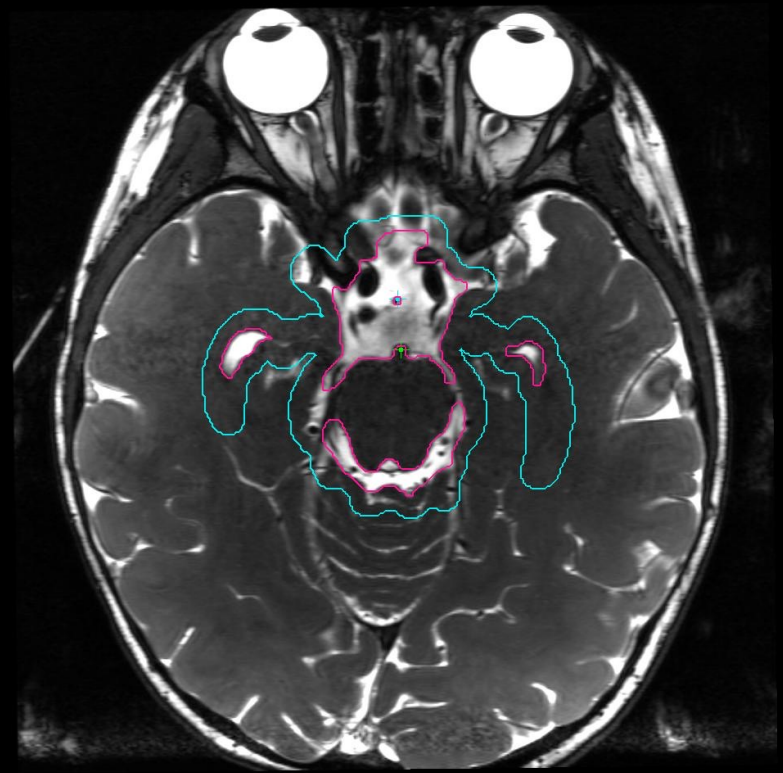
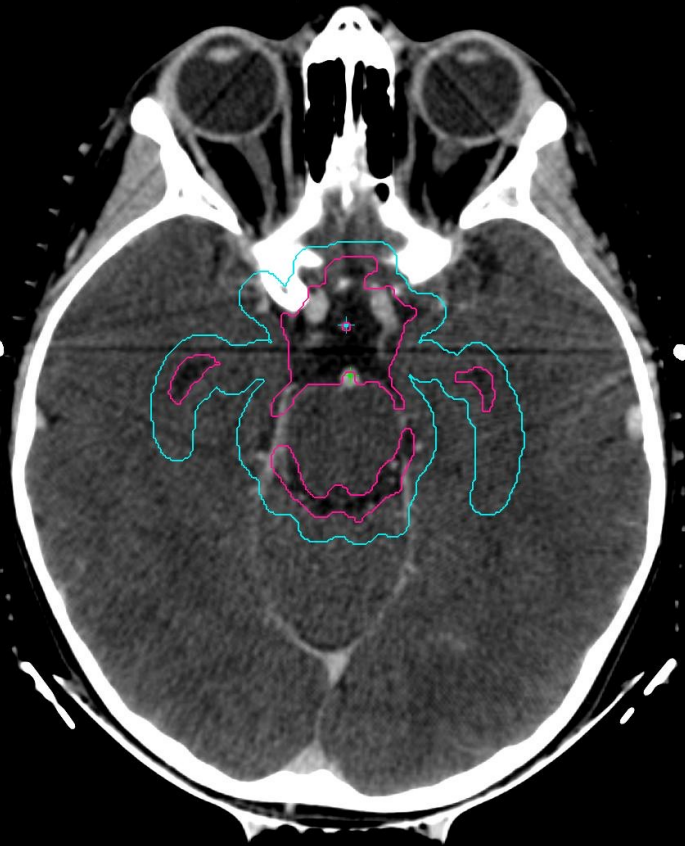


L R



■ WVVCTV

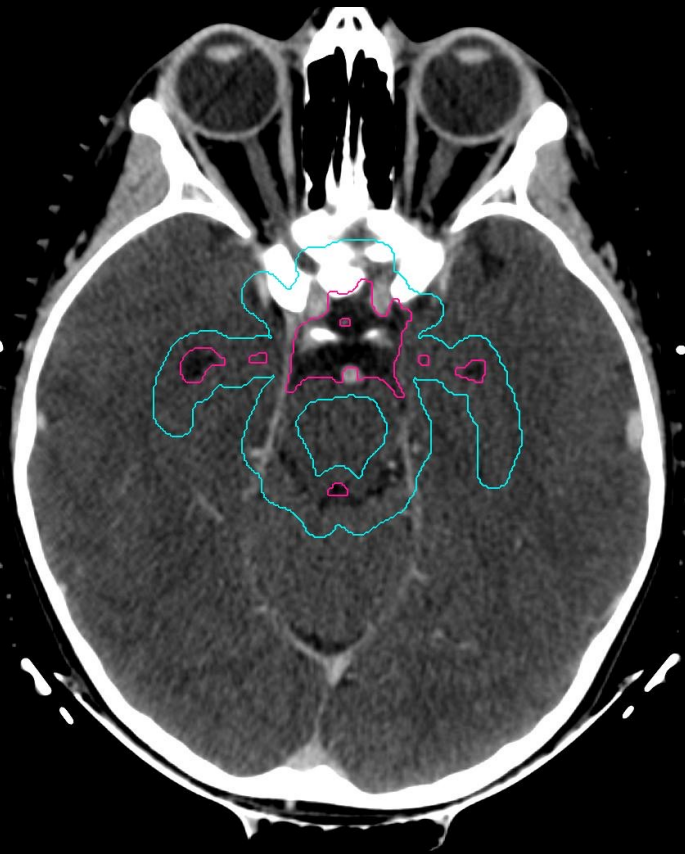■ WVPPTV



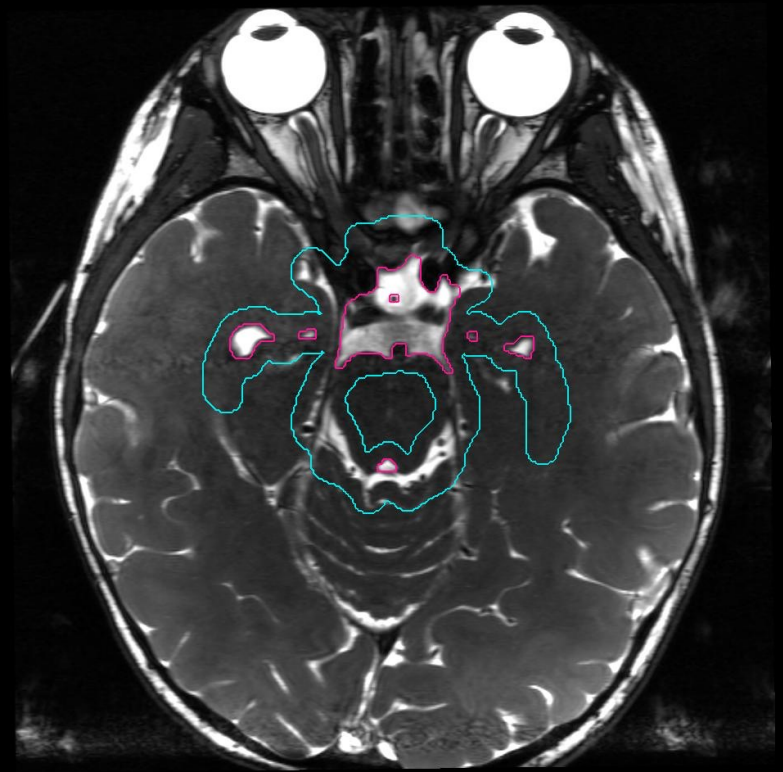


■ WVVCTV

■ WVPPTV



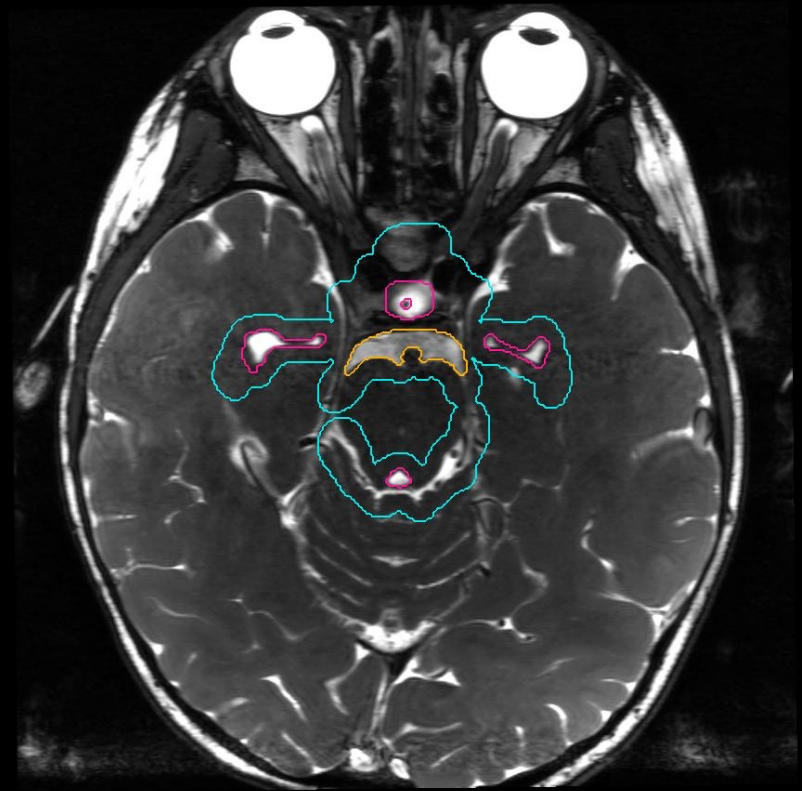
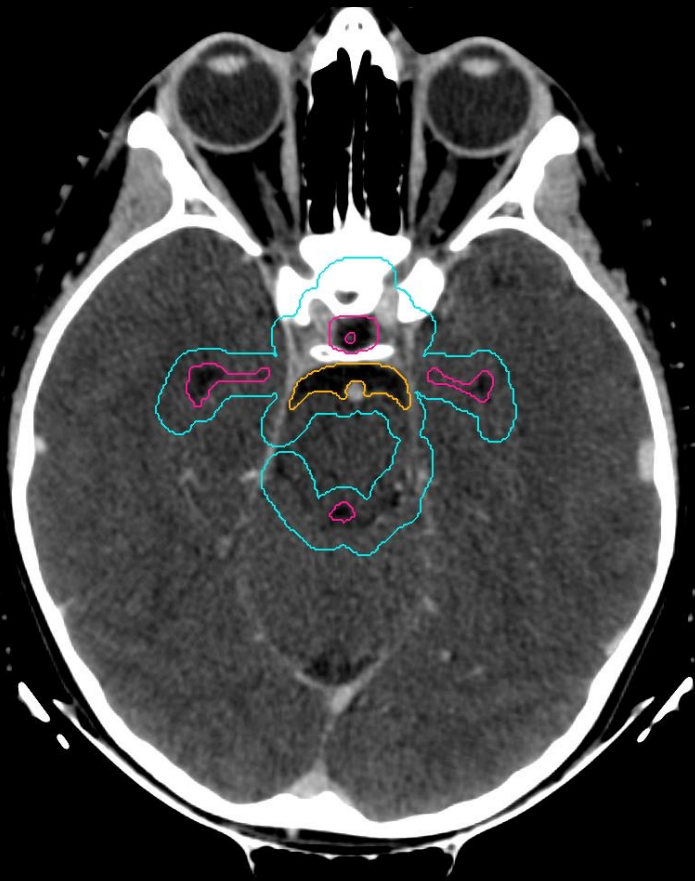
L R



WVVCTV

prepontine cistern

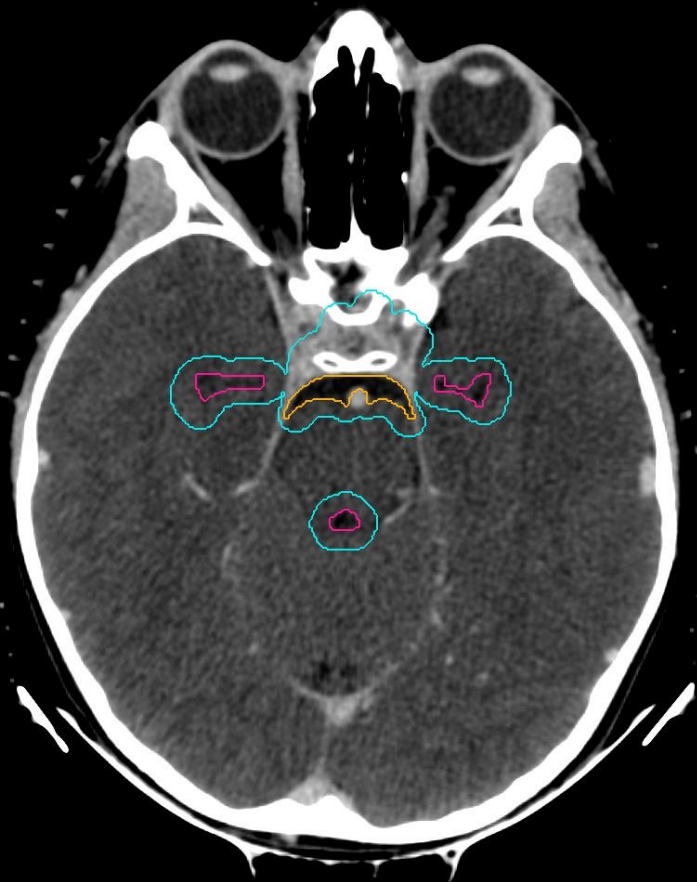WVVPTV



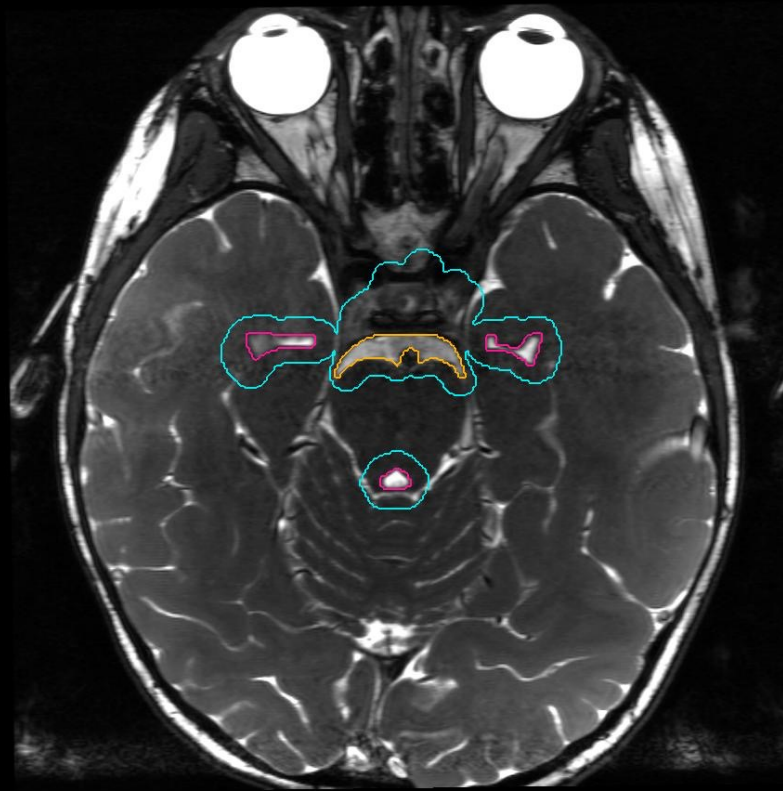
WVCTV

prepontine cistern

WVPVTV



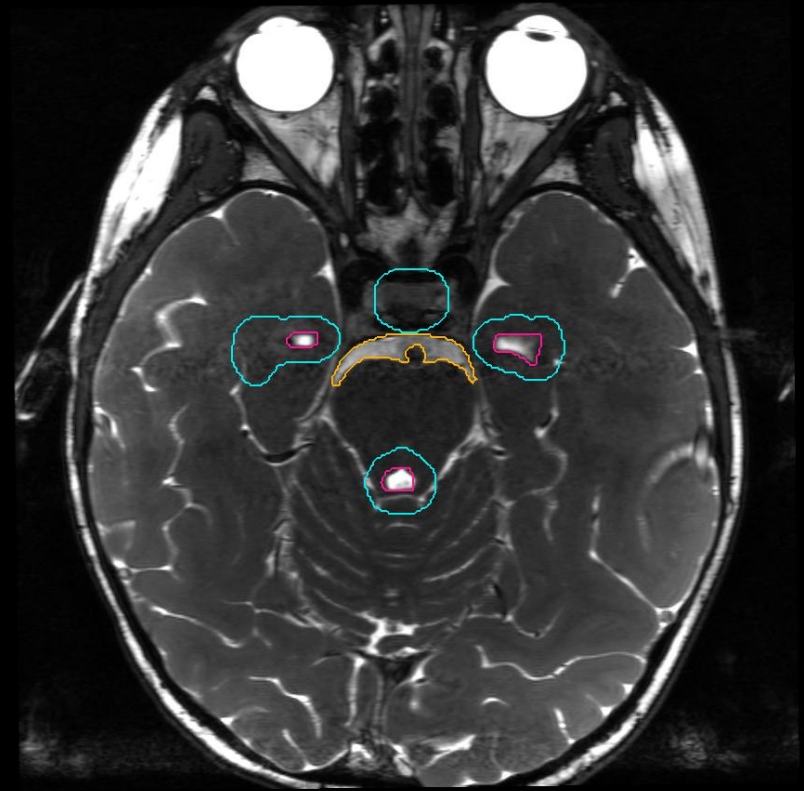
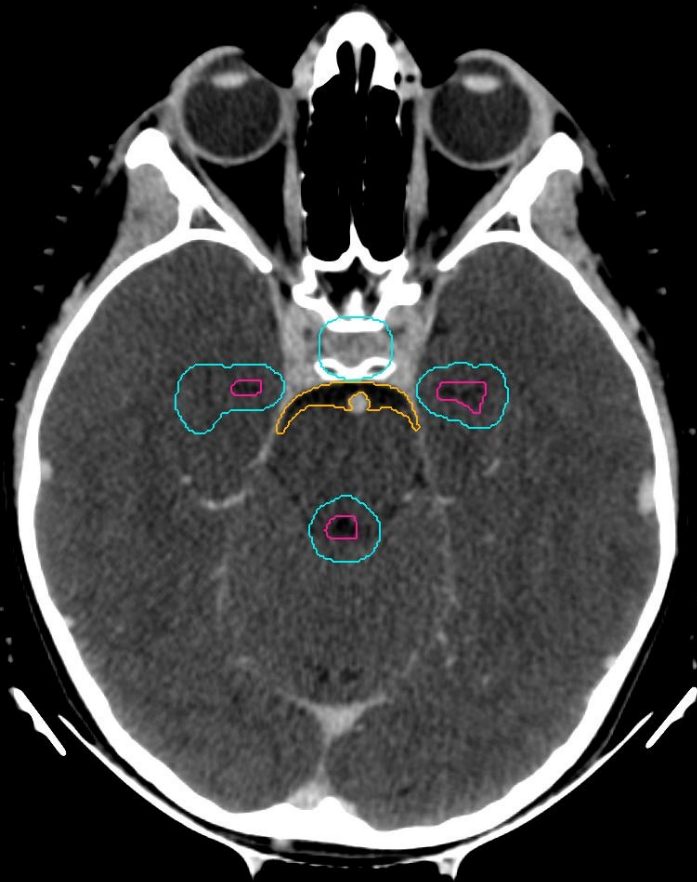
L R



WVCTV

prepontine cistern

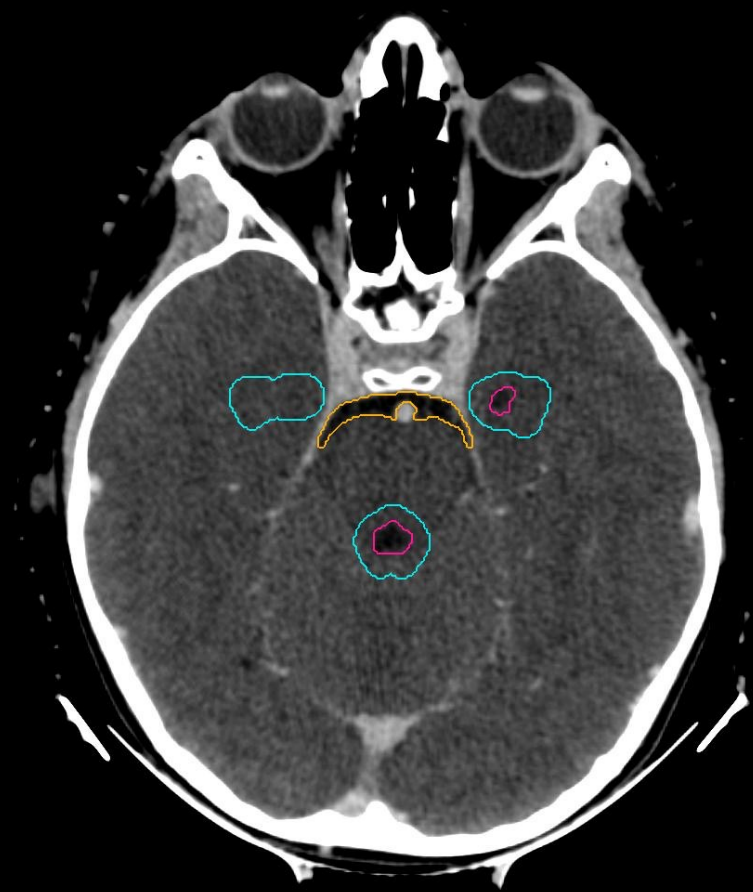
WVPV



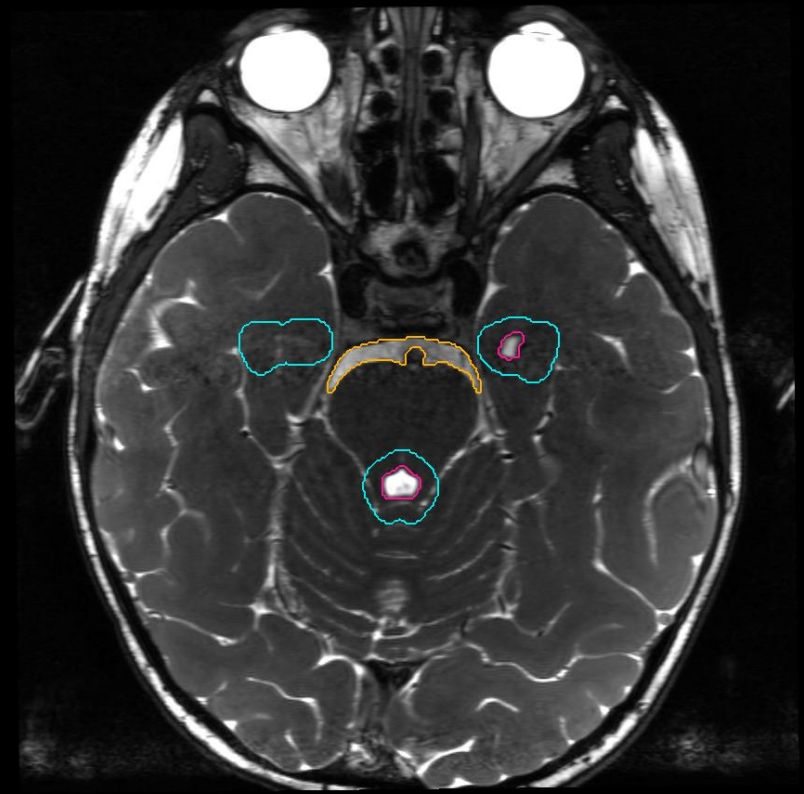
WVVCTV

prepontine cistern

WVVPTV



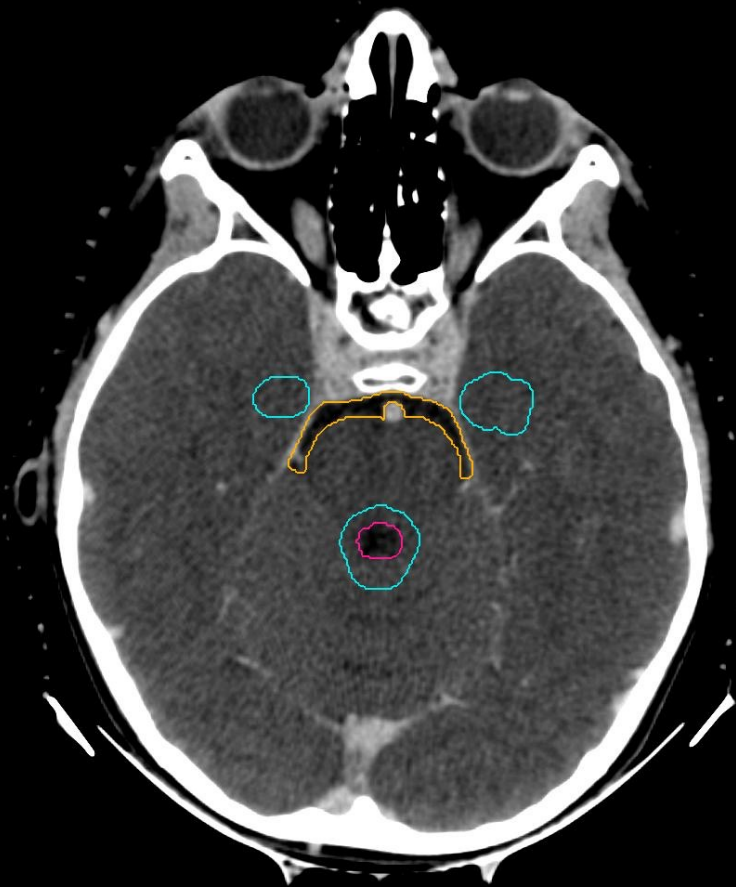
L R



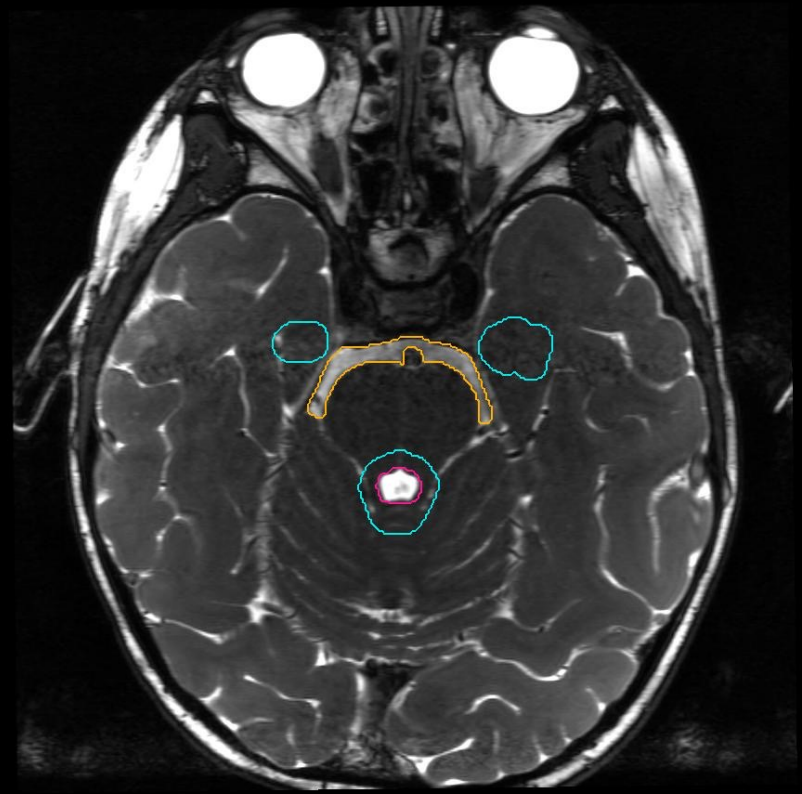
WVVCTV

prepontine cistern

WVVPTV



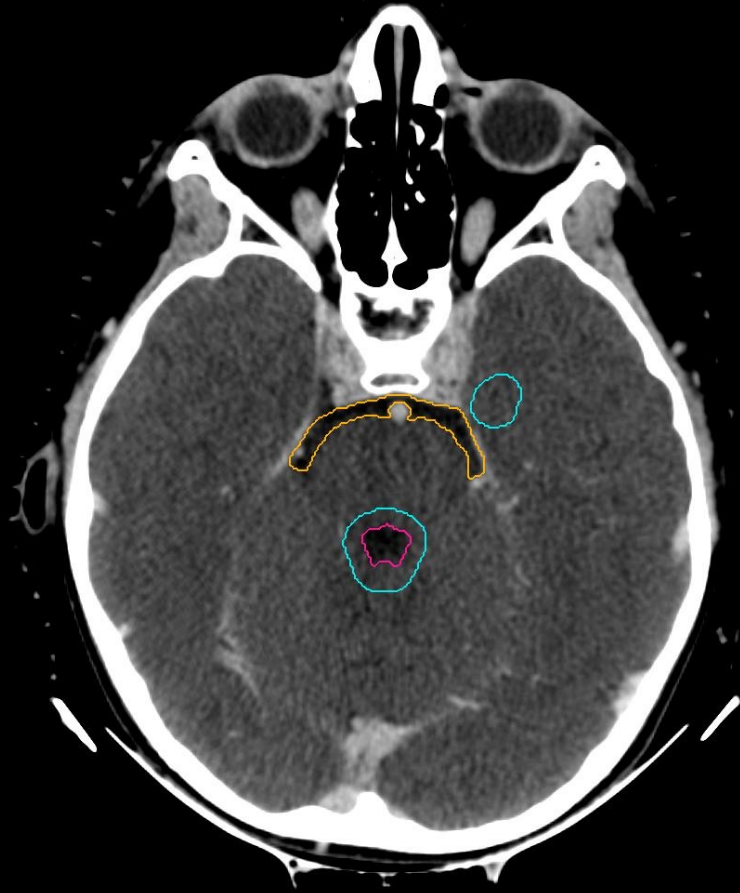
L R



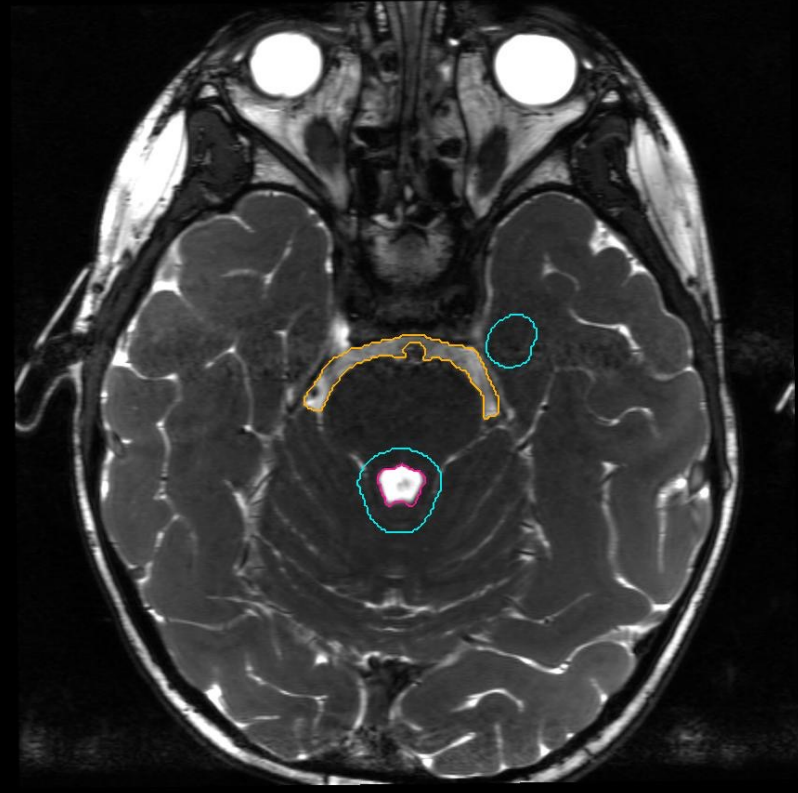
WVCTV

prepontine cistern

WVPV



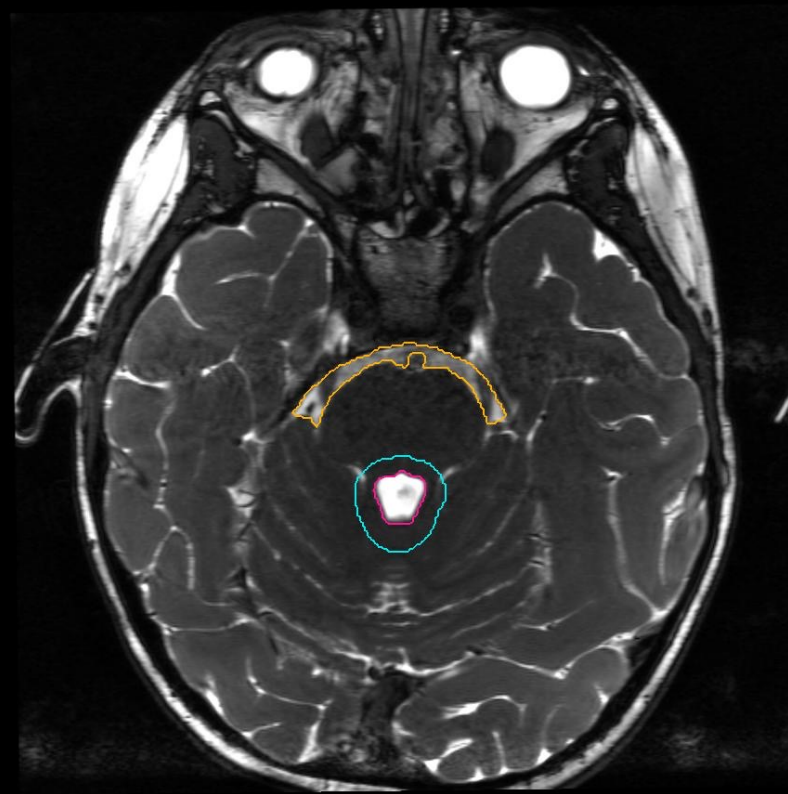
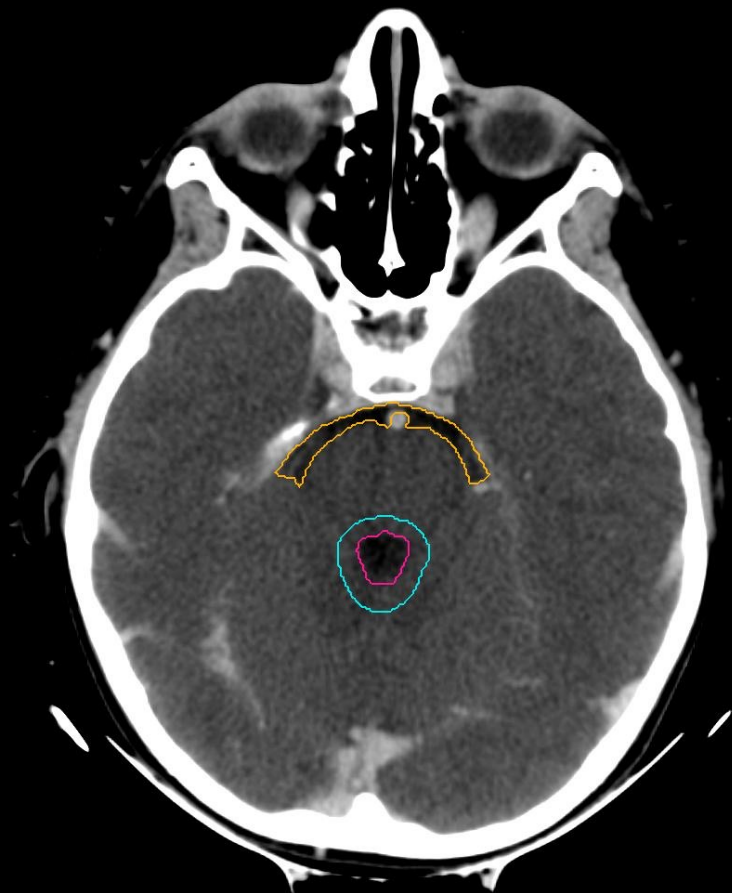
L R



WVVCTV

prepontine cistern

WVVPTV



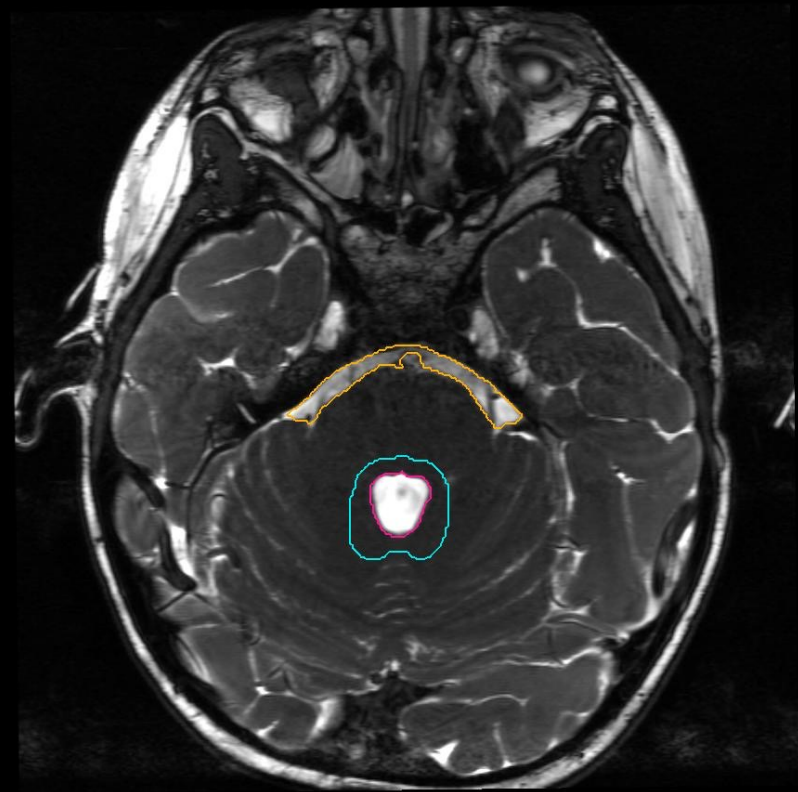
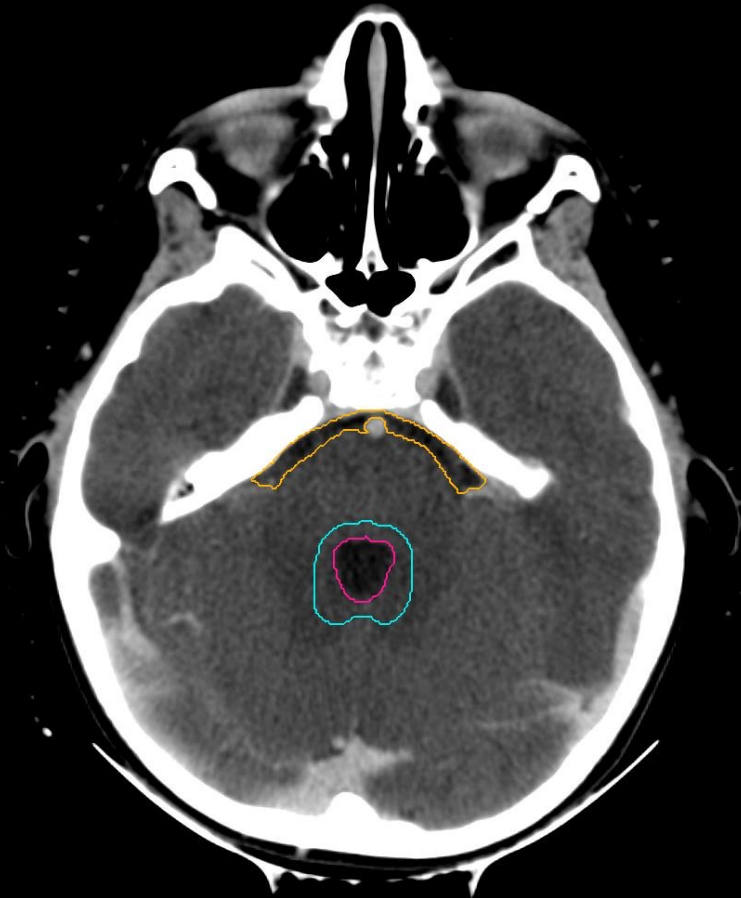
fourth ventricle, prepontine cistern



WVVCTV

prepontine cistern

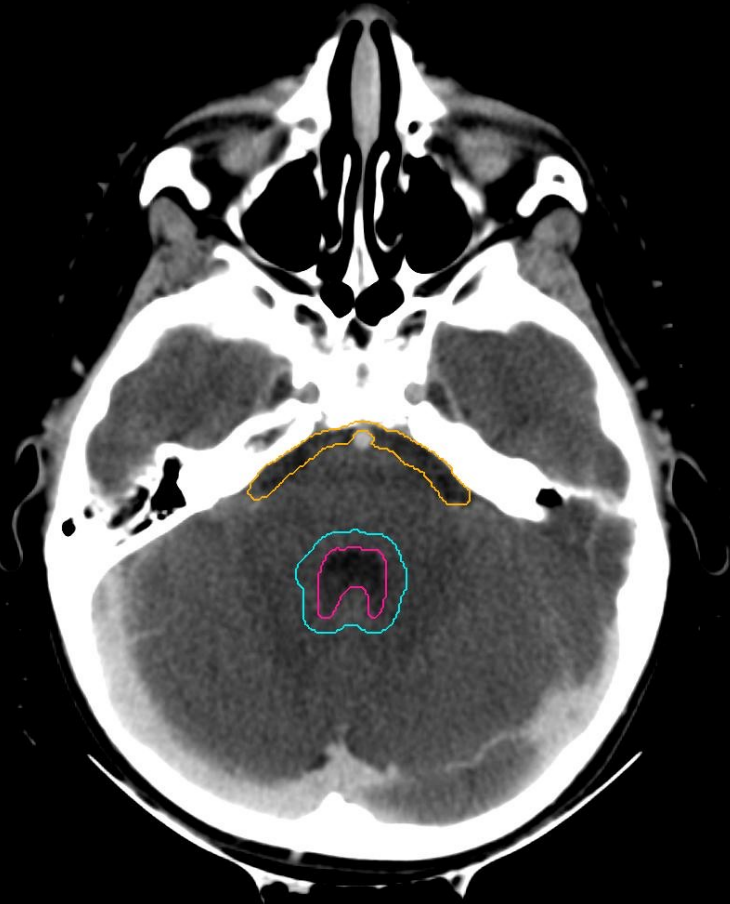
WVVPTV



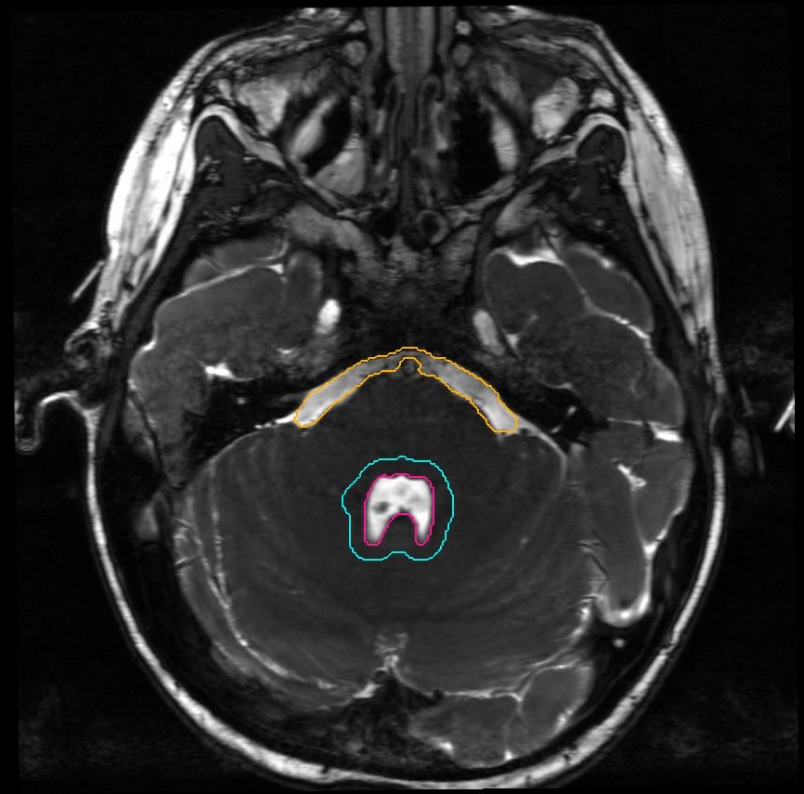
WVVCTV

prepontine cistern

WVVPTV



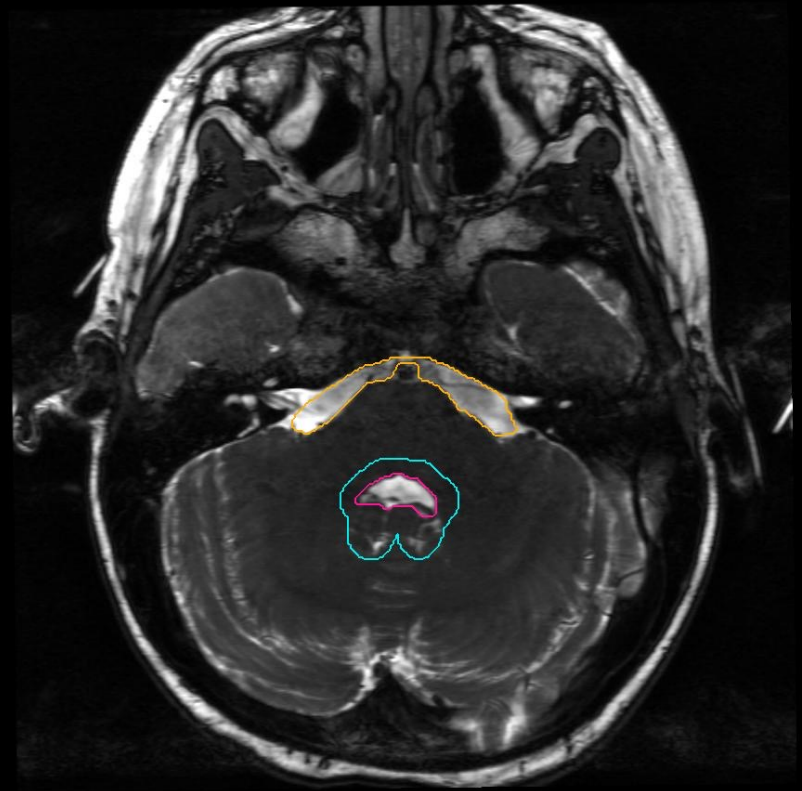
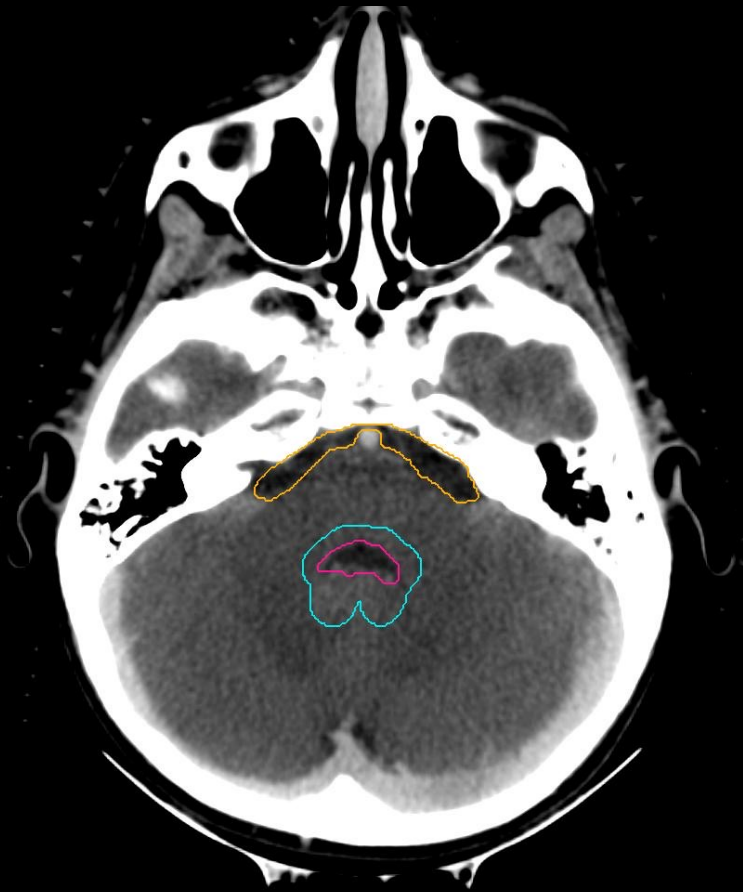
L R



WVVCTV

prepontine cistern

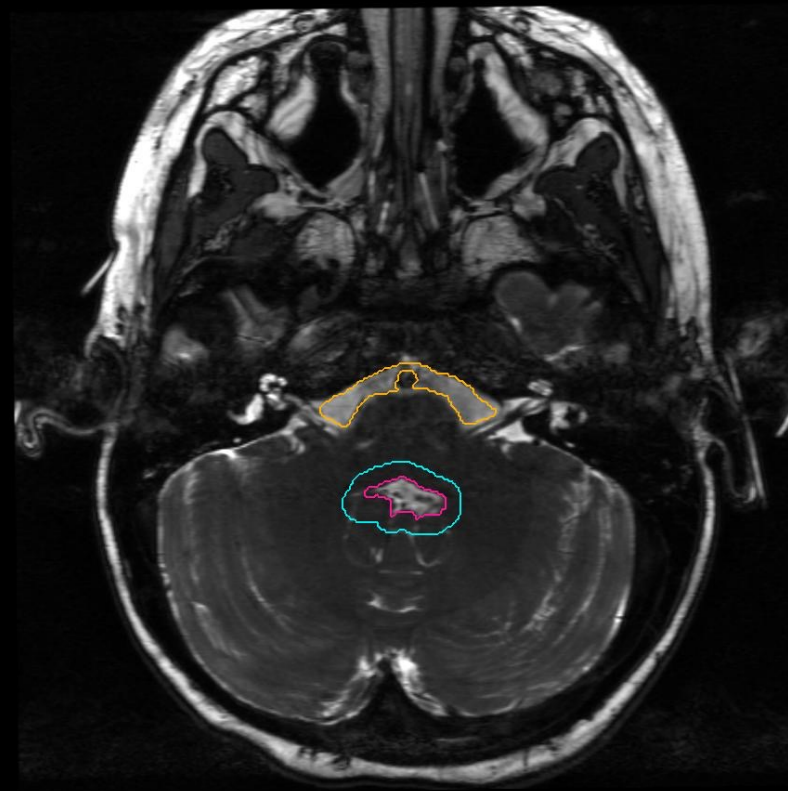
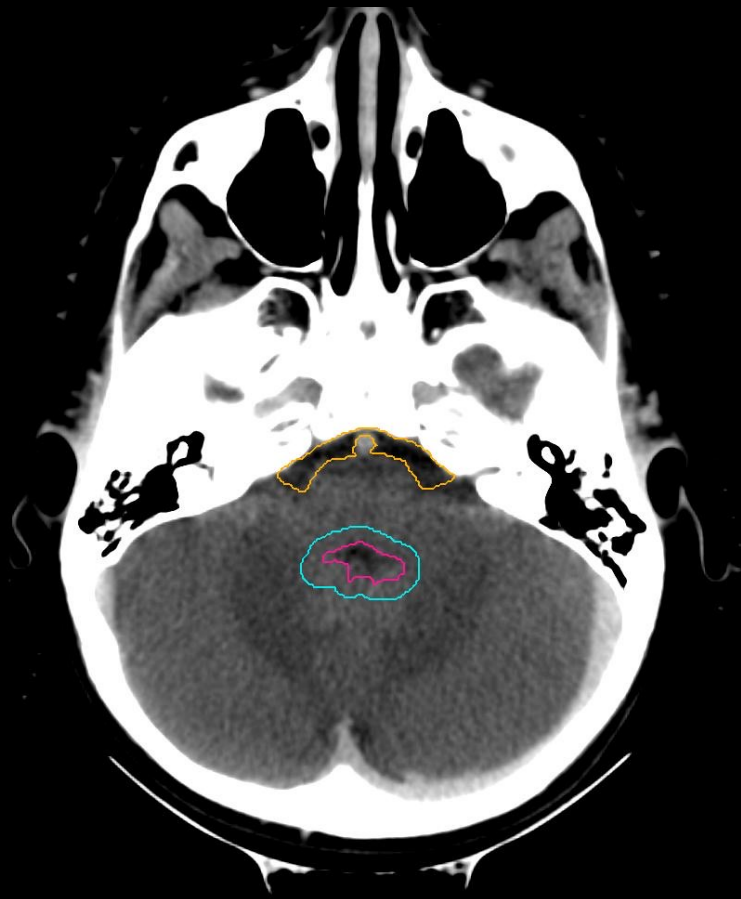
WVVPTV



WVCTV

prepontine cistern

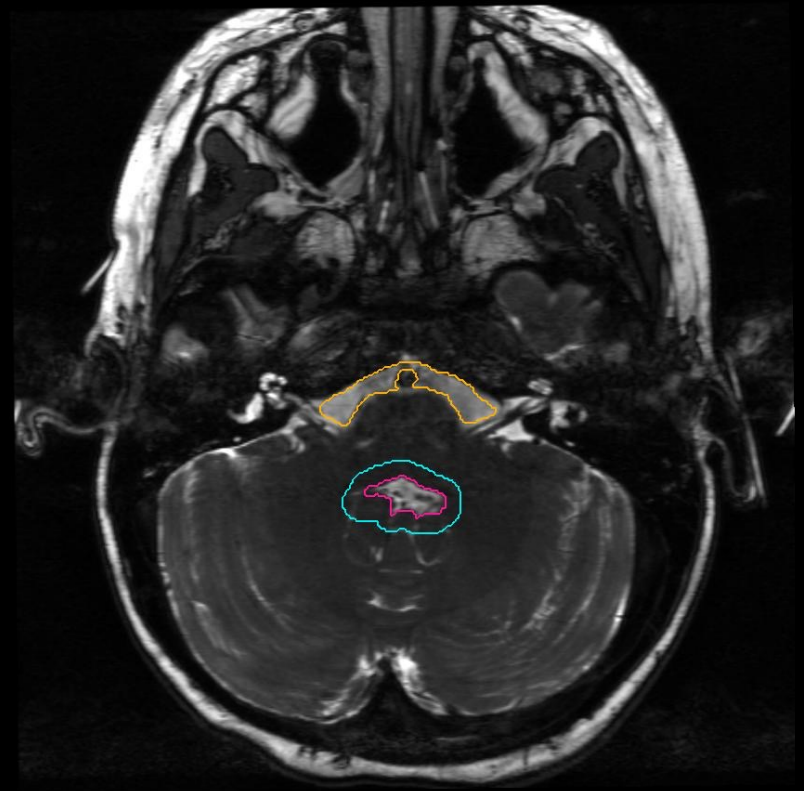
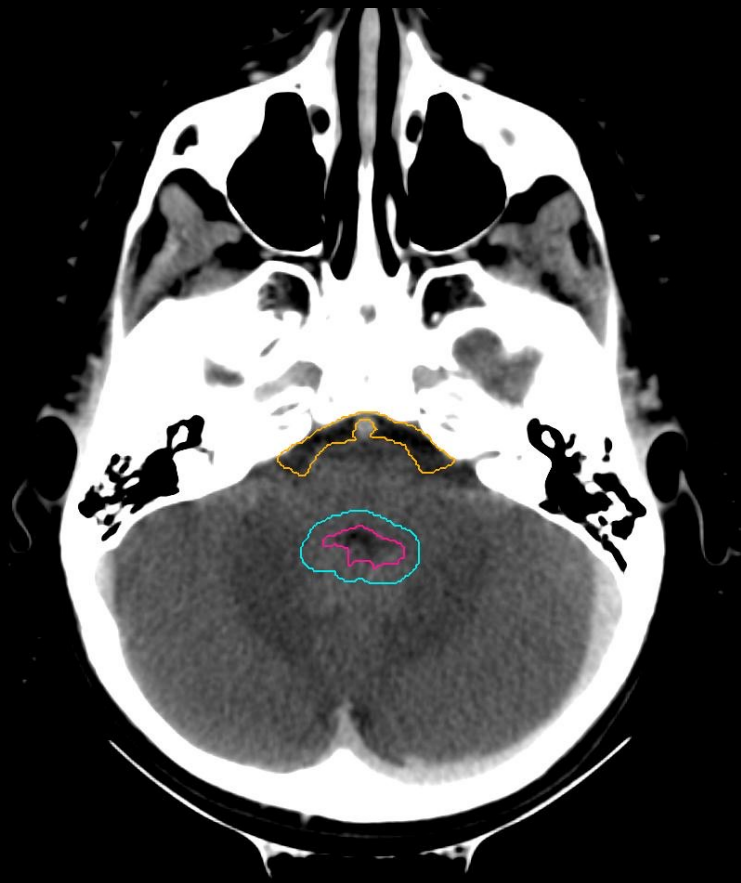
WVPV



WVCTV

prepontine cistern

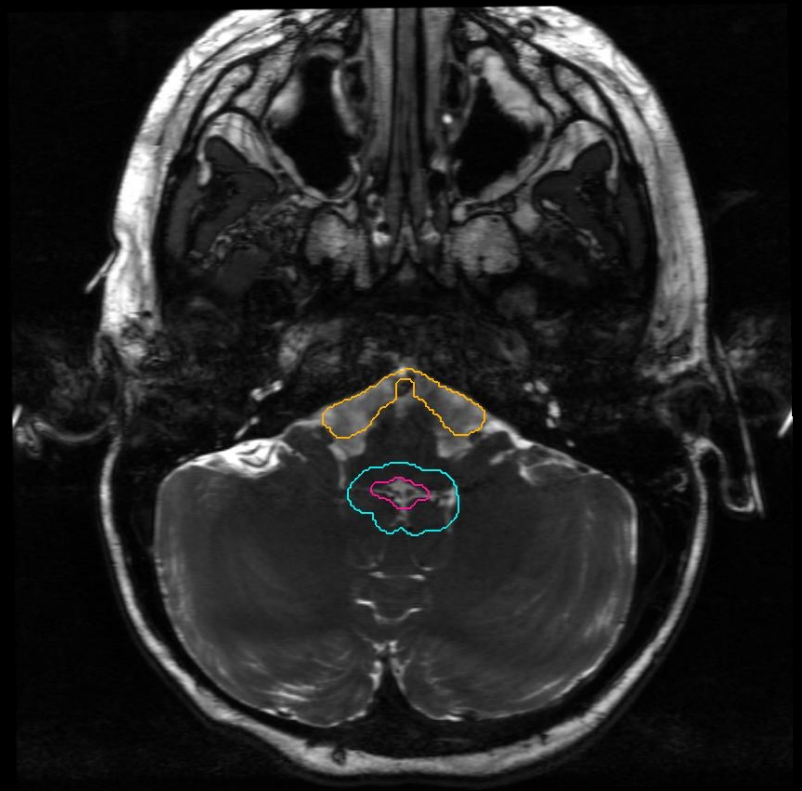
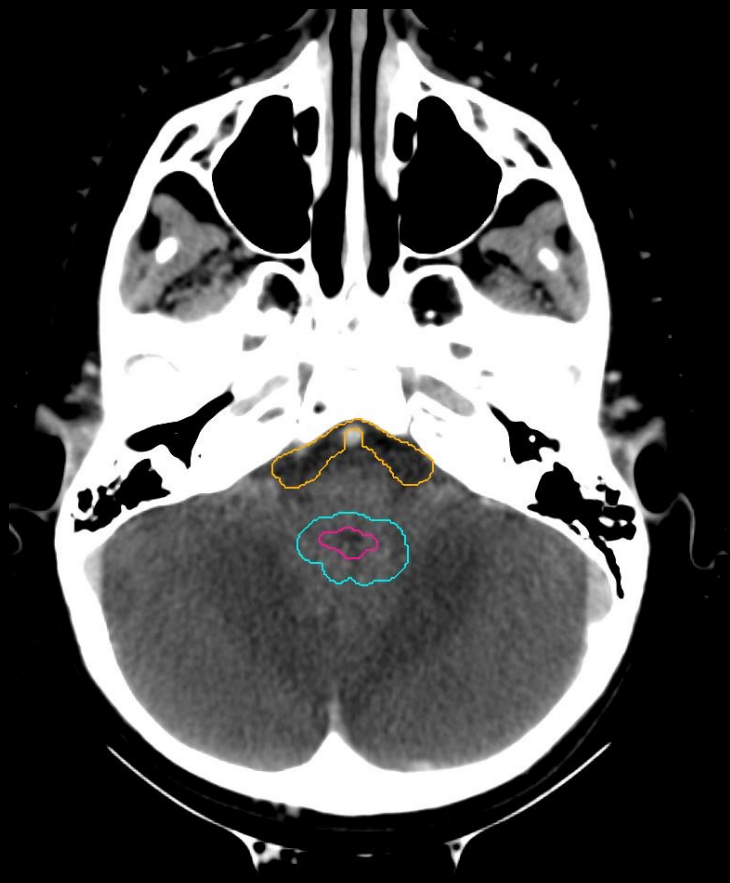WVPV



WVCTV

prepontine cistern

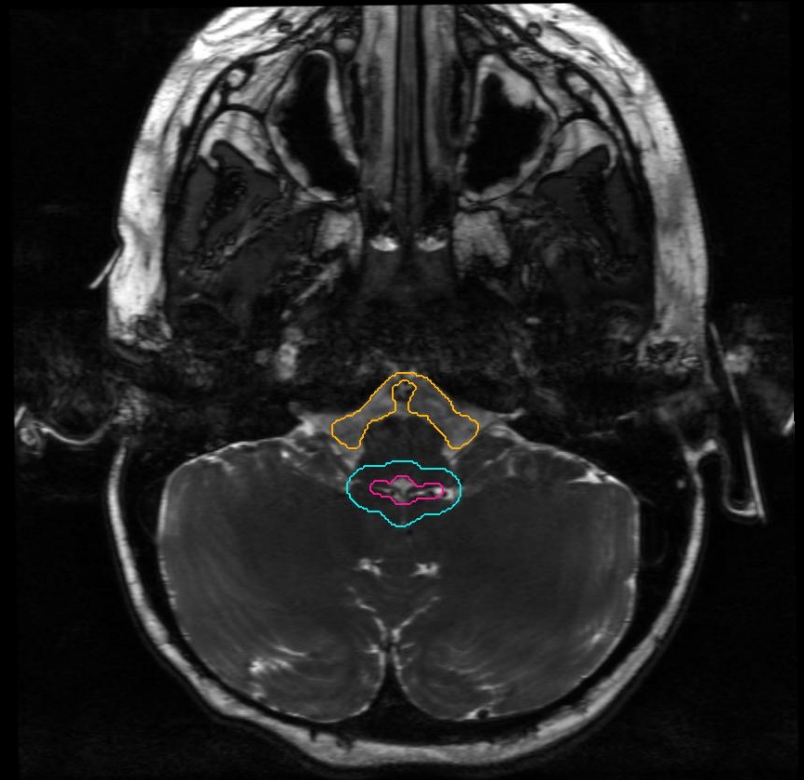
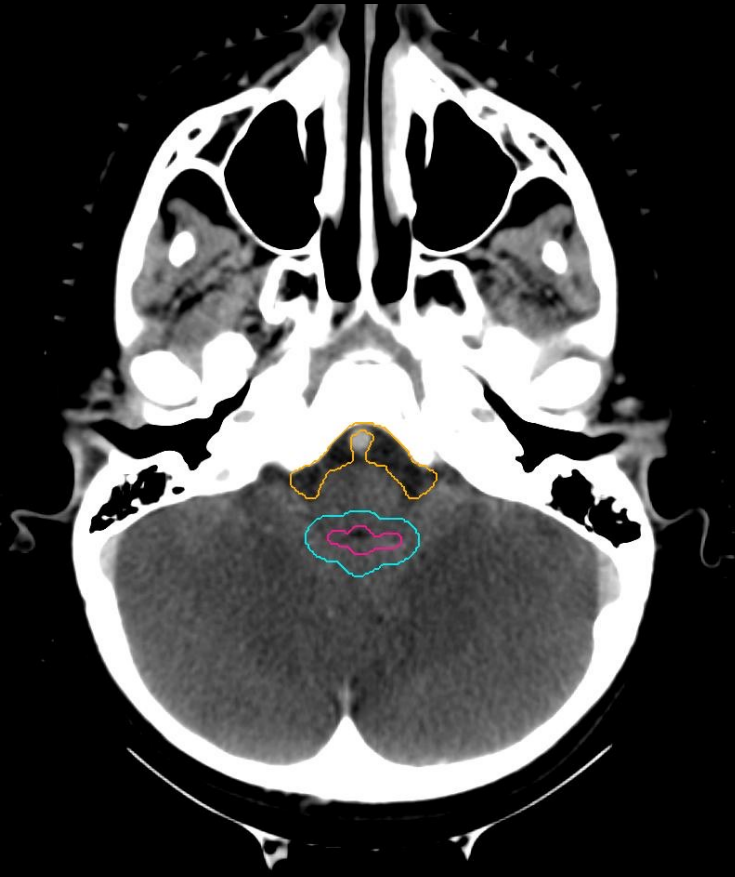
WVPV



WVCTV

prepontine cistern

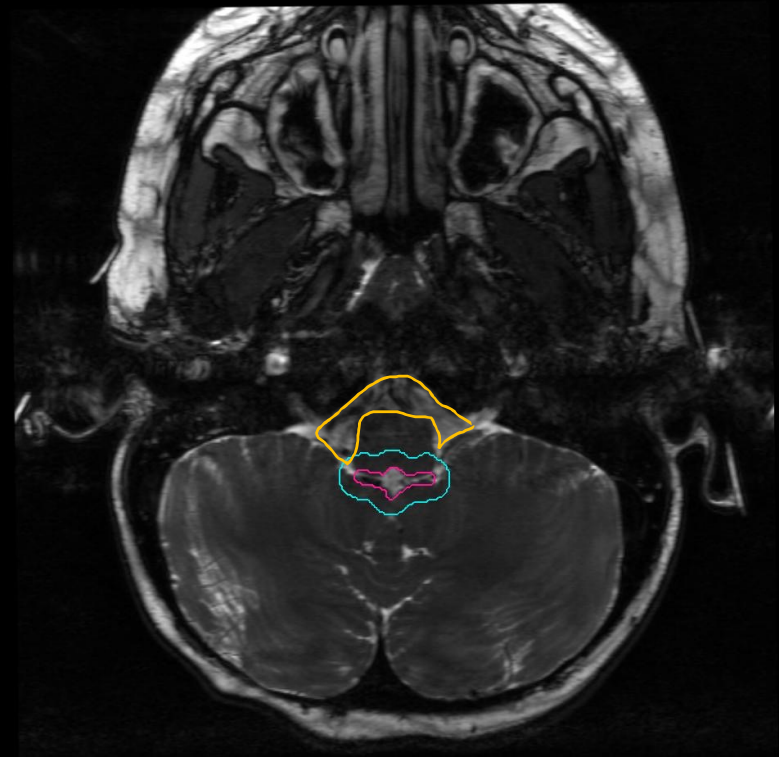
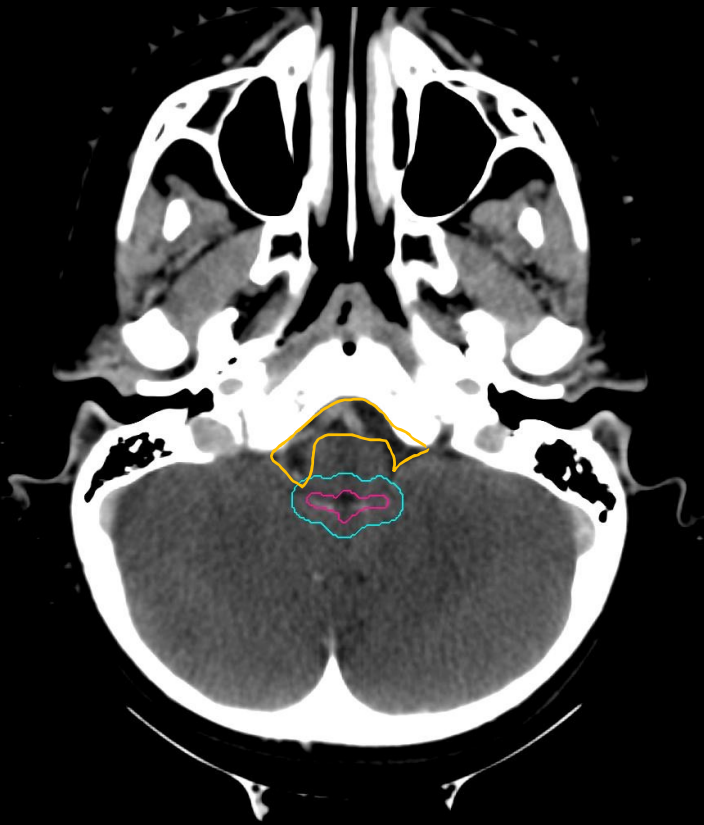WVPVTV



WVCTV

prepontine cistern

WVPV

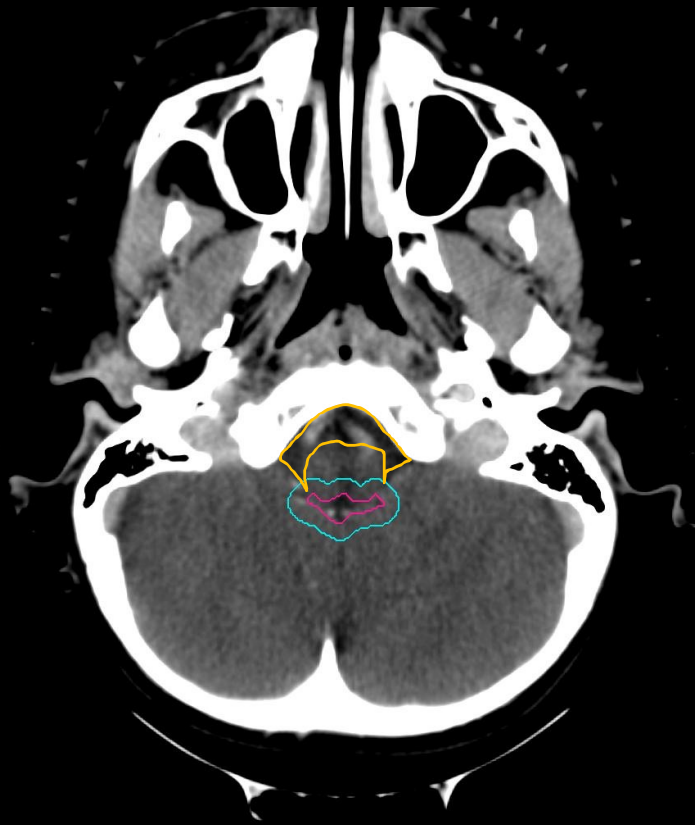



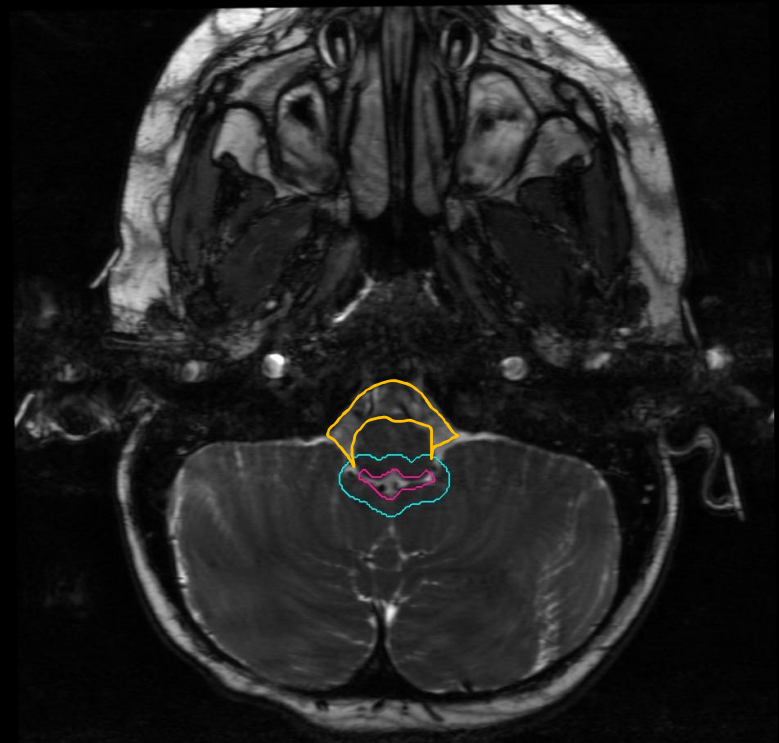
WVCTV

prepontine cistern

WVPV



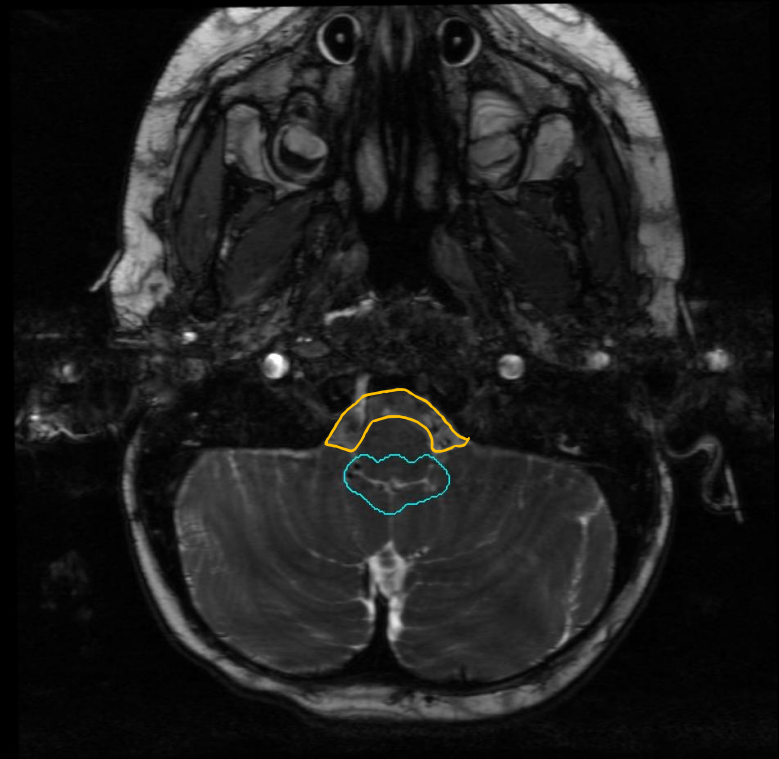

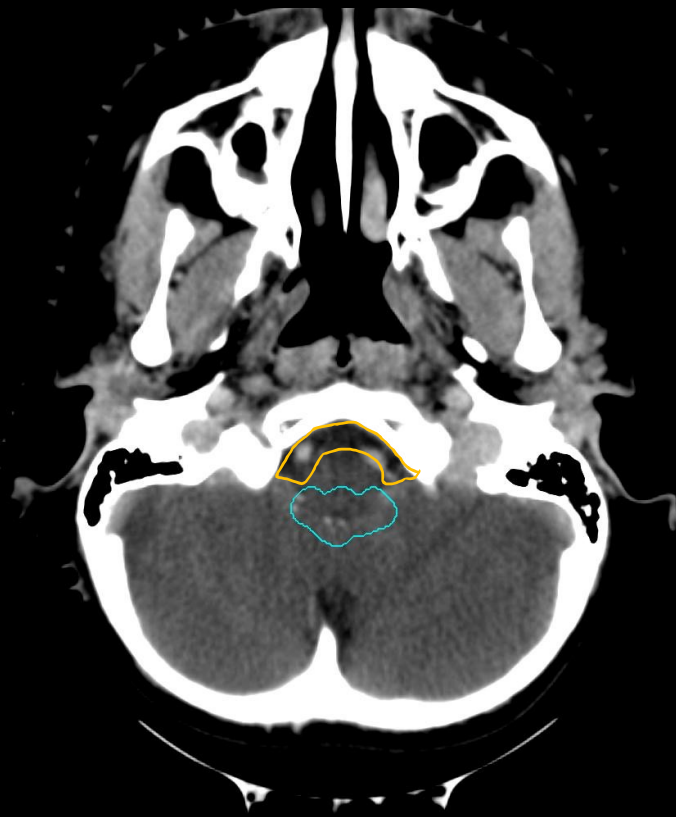
L R



WVVCTV

prepontine cistern

WVVPTV



the inferior slice of WVVCTV and prepontine cistern combined (CTV\_WV) should be continuous with the superior slice of CTV\_Spine

Biopsy tract

Section b)

# Biopsy tract

- The WVV volume includes the biopsy tract used for tissue diagnosis
- This volume should not include spaces left by external ventricular drains (EVD) or ventriculoperitoneal (VP) shunts if no biopsy was taken from those spaces
- The contour should extend out to the dural surface and inner  $\frac{1}{2}$  of the calvarium

# Biopsy tract

- Use the planning CT (on brain windows) and T2 MRI to guide contouring of the biopsy tract
- The biopsy tract should be included in WVV volume
  - It does not need to be a separate structure in clinical plans



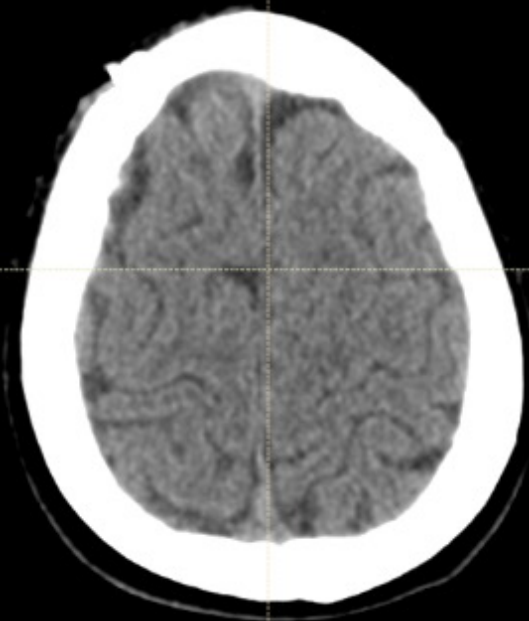
Biopsy tract



Ventricles

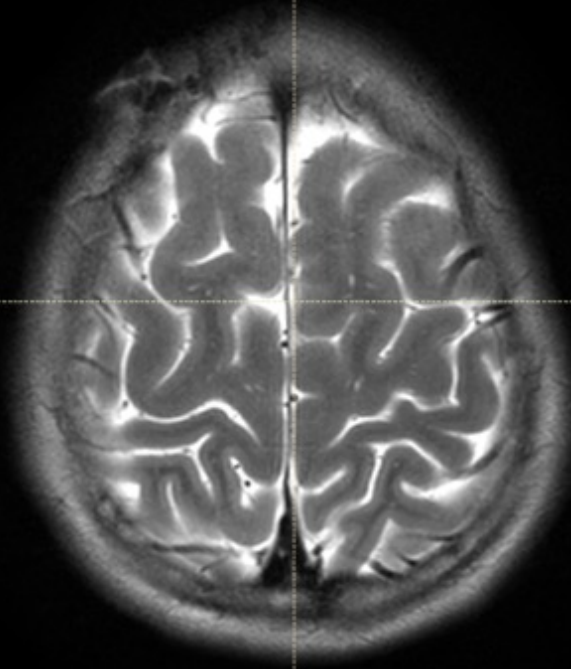


WVV



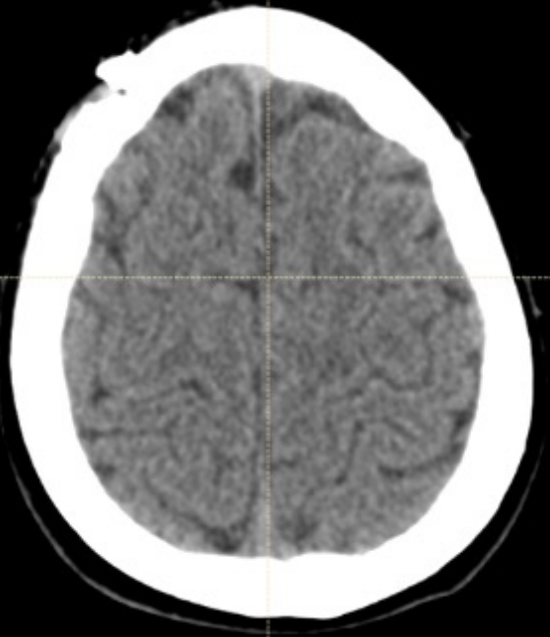
0 1 2 3 4 cm

Navigation icons: Home, Search, Refresh, Close



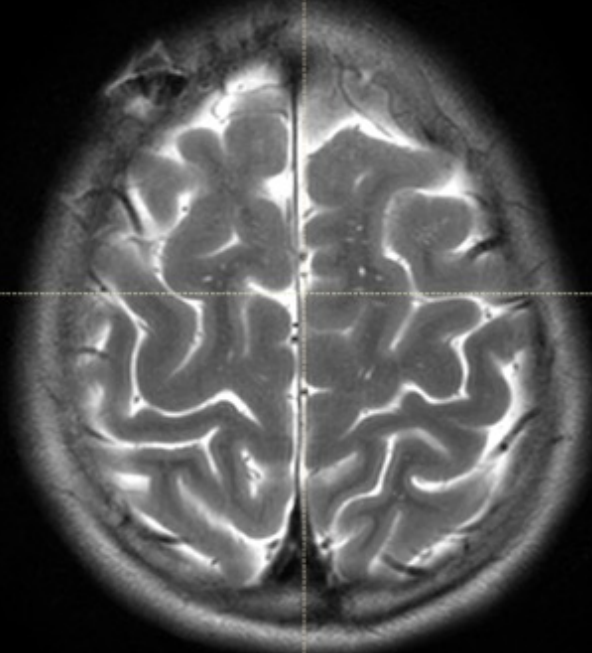
0 1 2 3 4 cm

Navigation icons: Home, Search, Refresh, Close



0 1 2 3 4 cm

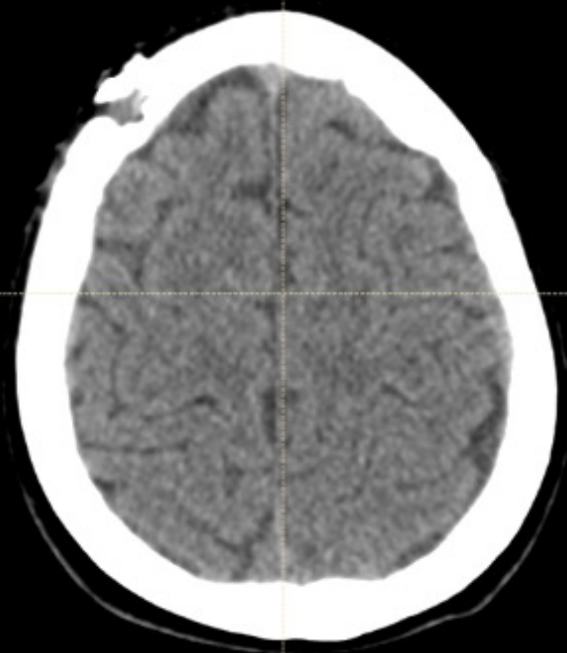
Navigation icons: Home, Search, Refresh, Close



0 1 2 3 4 cm

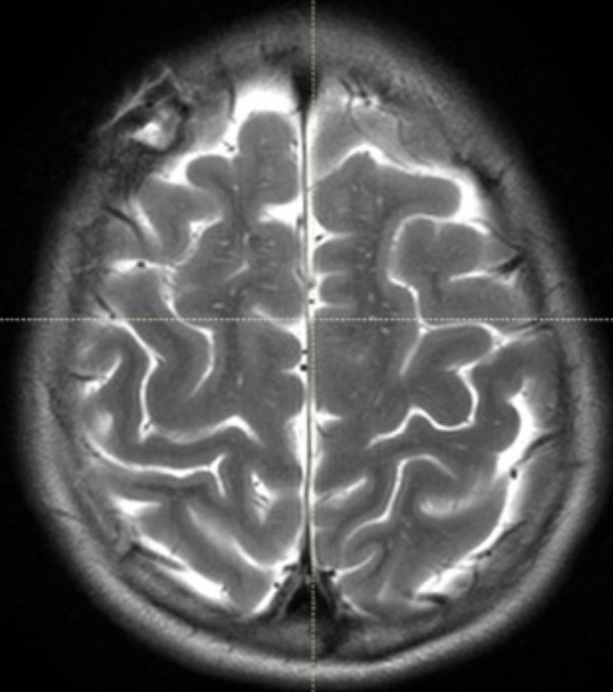
Navigation icons: Home, Search, Refresh, Close





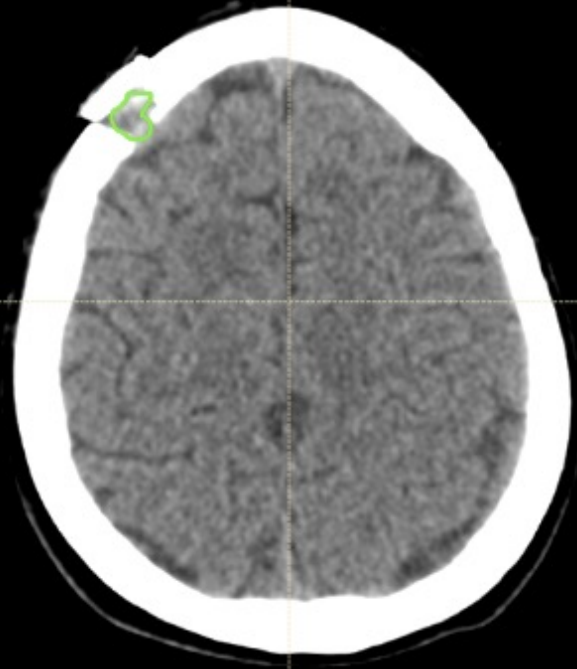
0 1 2 3 4 cm

Navigation icons: Home, Search, and Refresh.

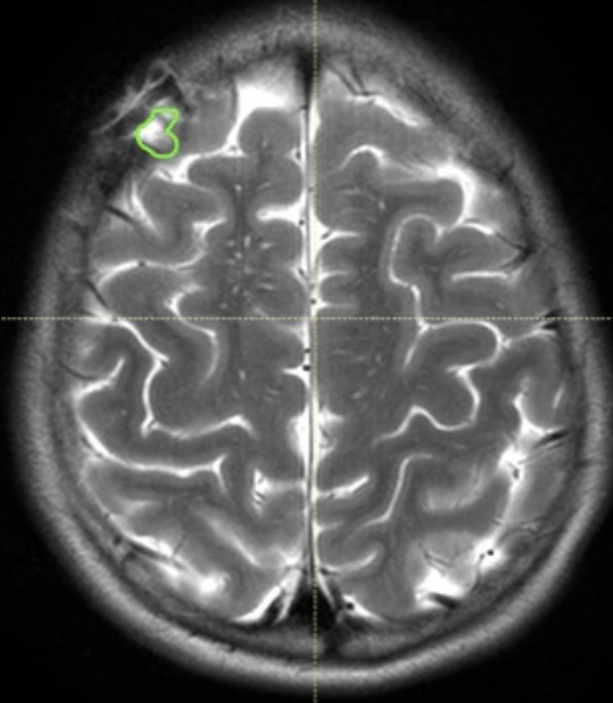


0 1 2 3 4 cm

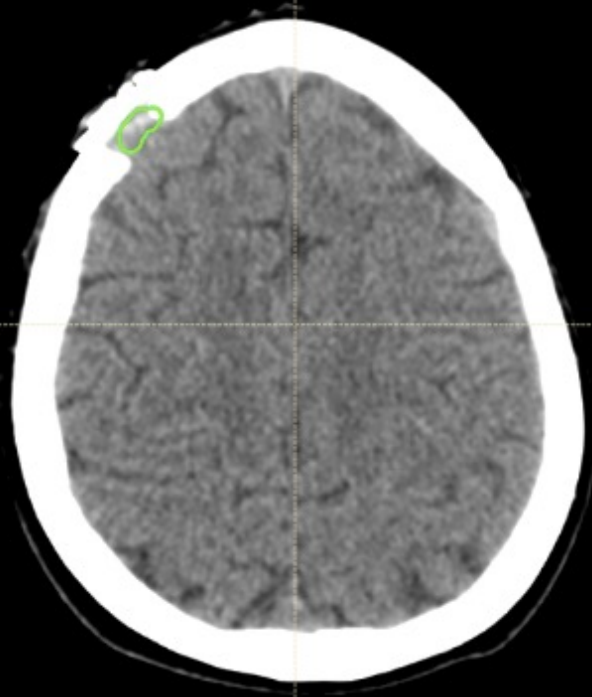
Navigation icons: Home, Search, and Refresh.



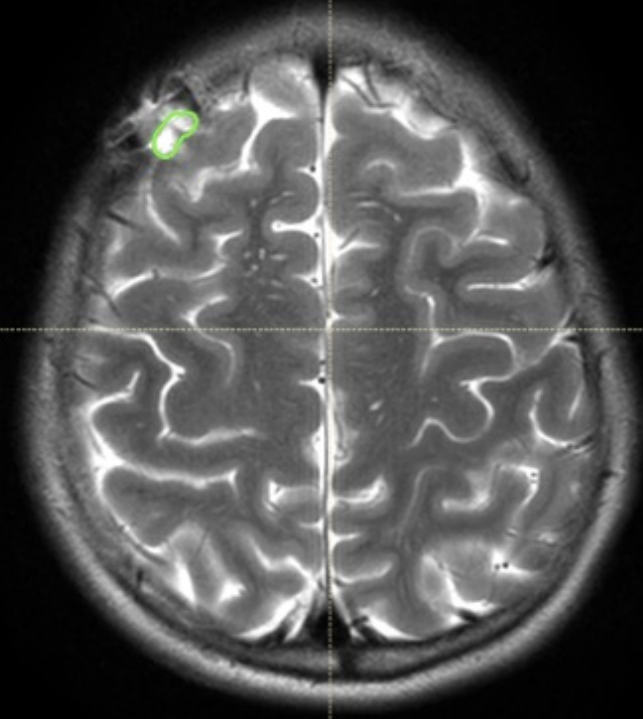
0 1 2 3 4 cm



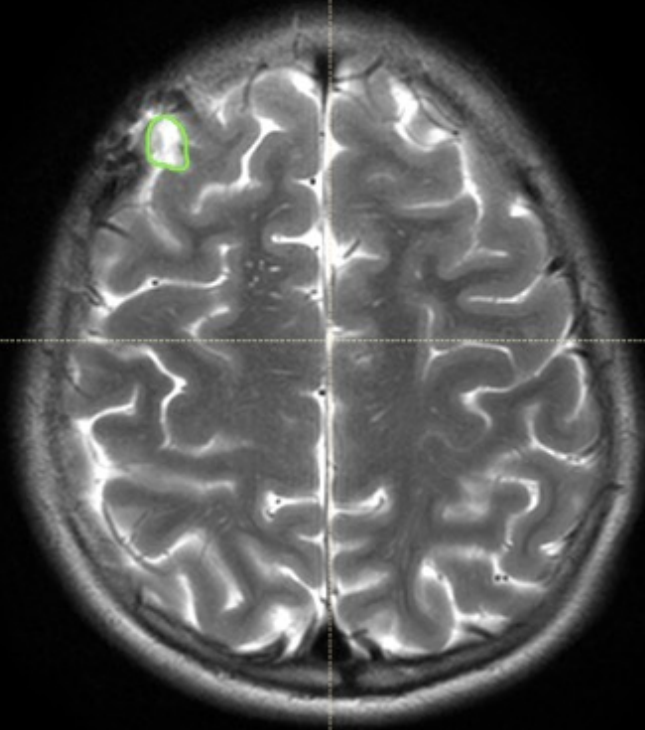
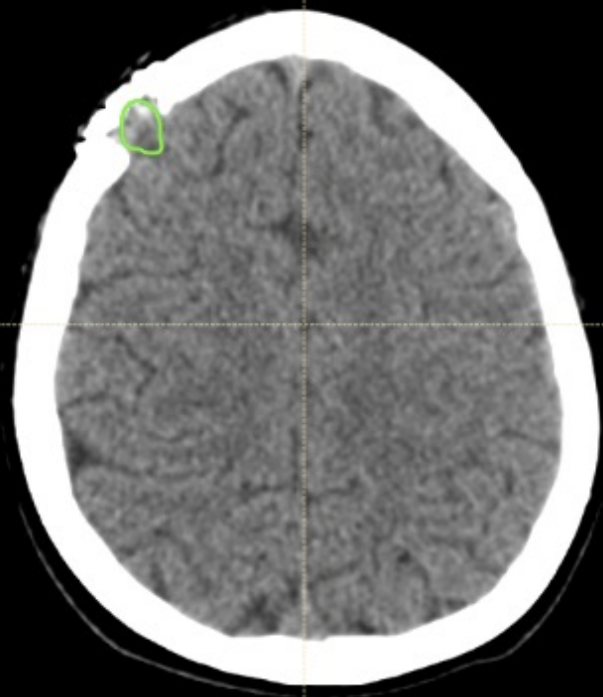
0 1 2 3 4 cm

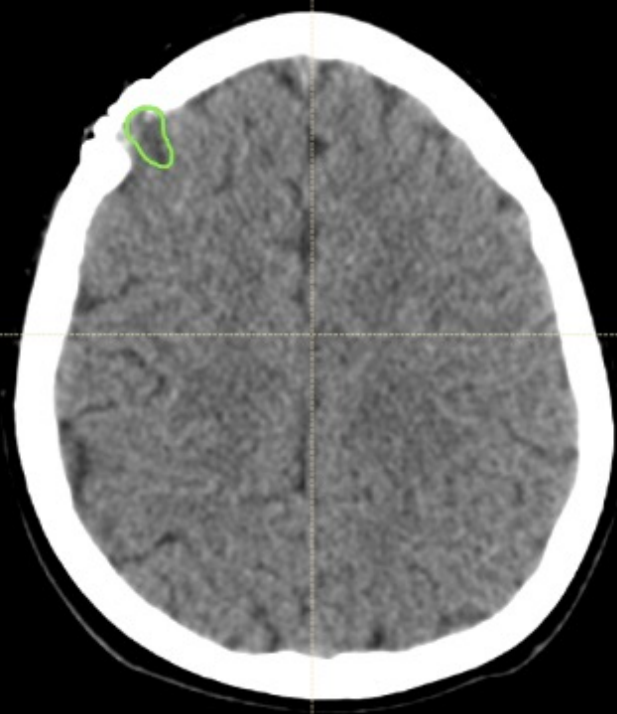


0 1 2 3 4 cm

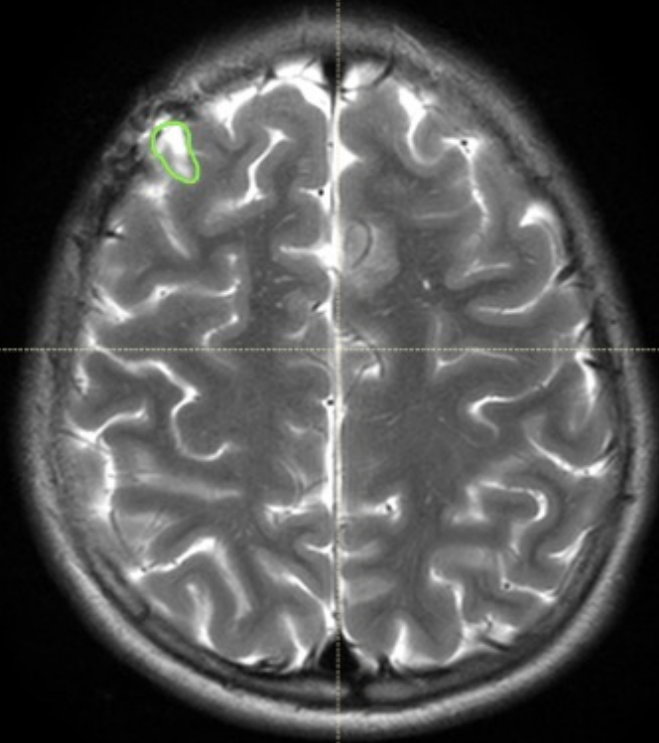


0 1 2 3 4 cm

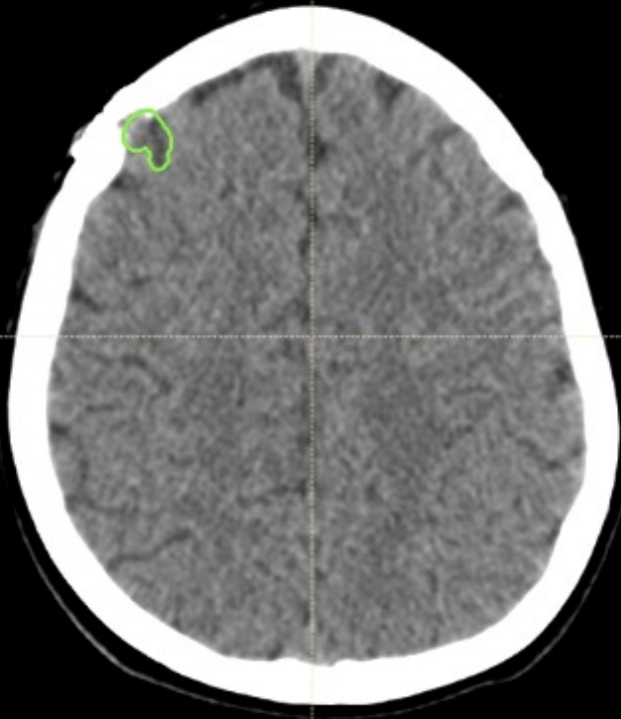




0 1 2 3 4 cm

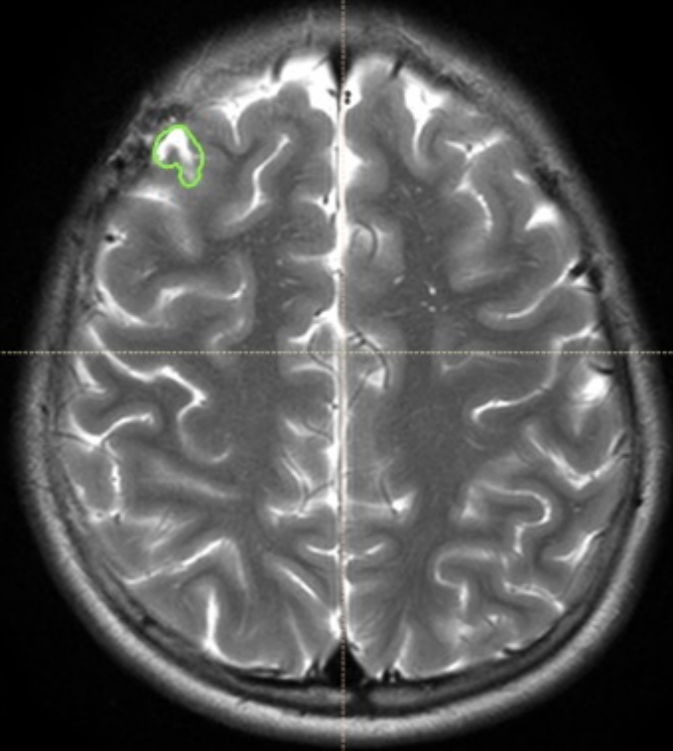


0 1 2 3 4 cm



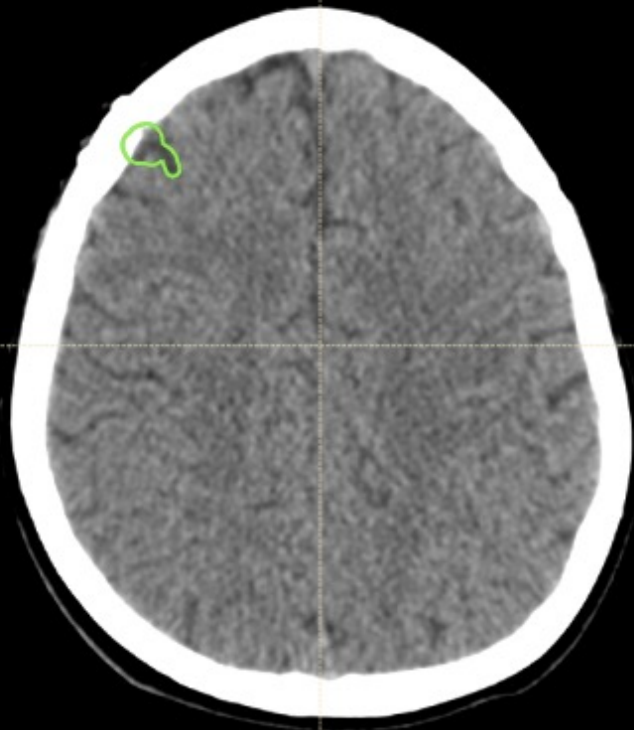
0 1 2 3 4 cm

Navigation icons: Home, Search, Refresh, Close

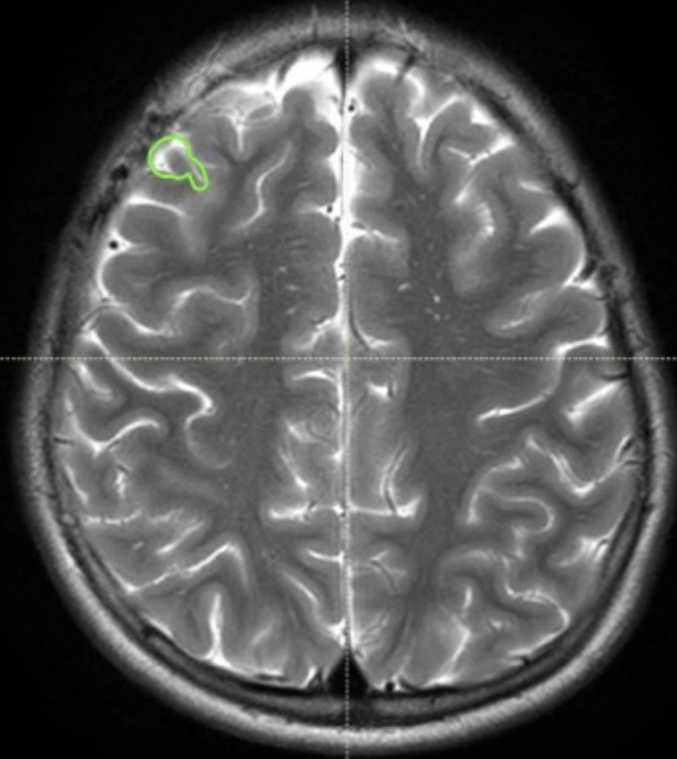


0 1 2 3 4 cm

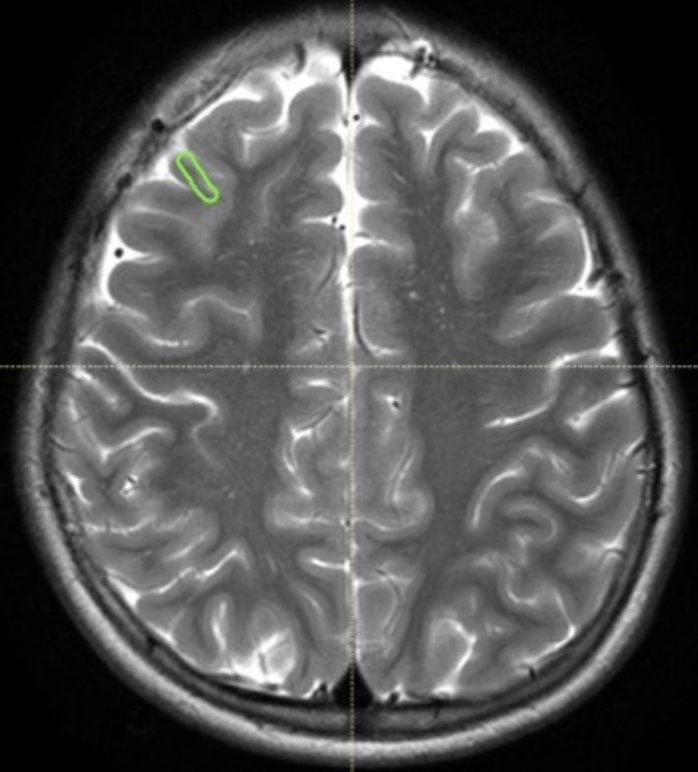
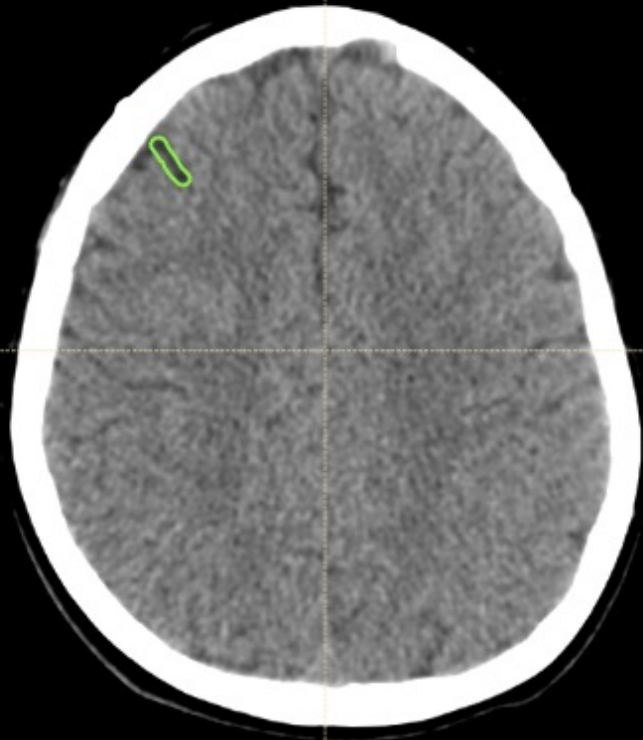
Navigation icons: Home, Search, Refresh, Close



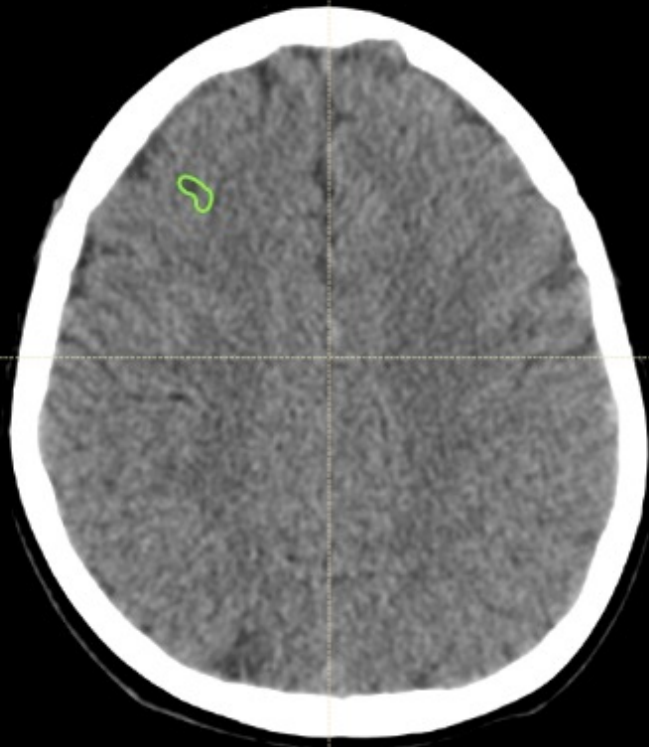
0 1 2 3 4 cm



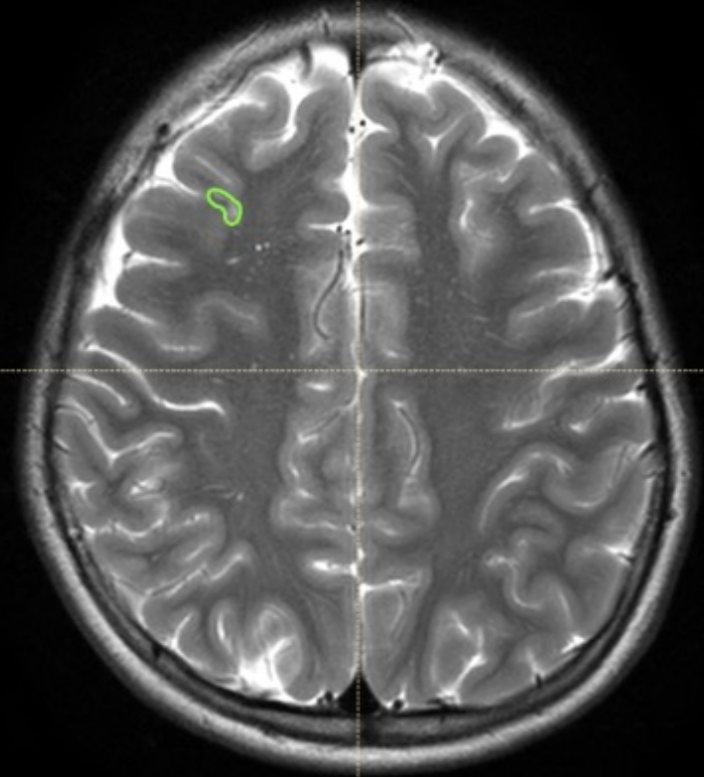
0 1 2 3 4 cm



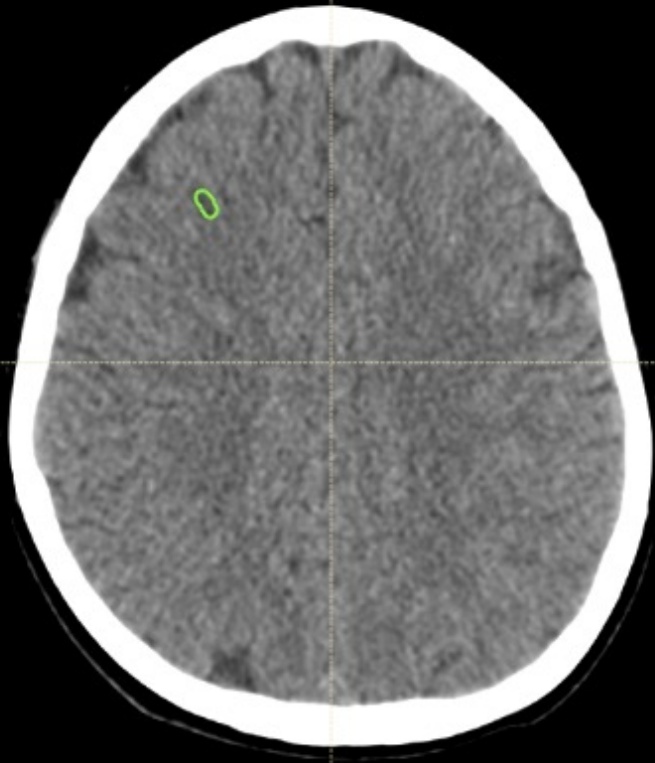




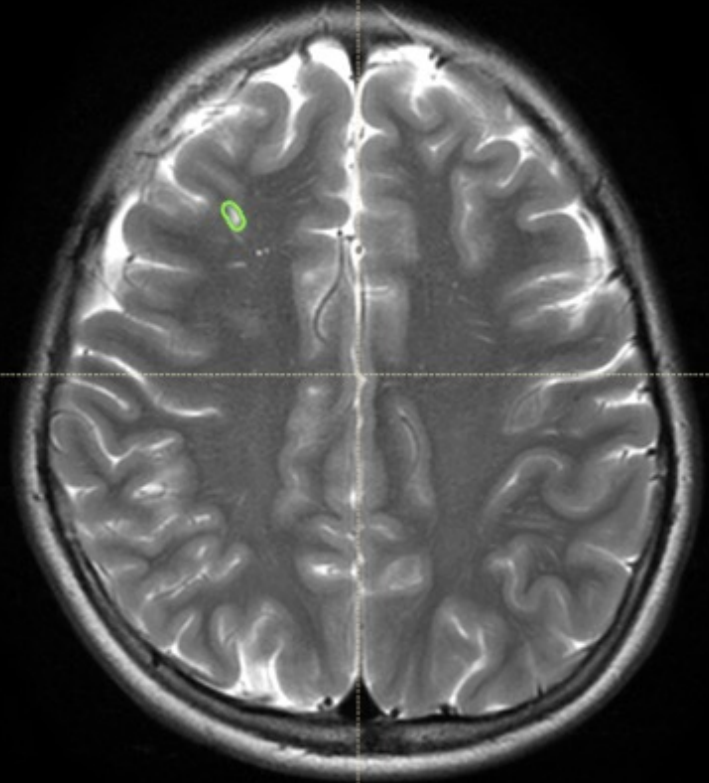
Navigation icons: Home, Search, and other controls.



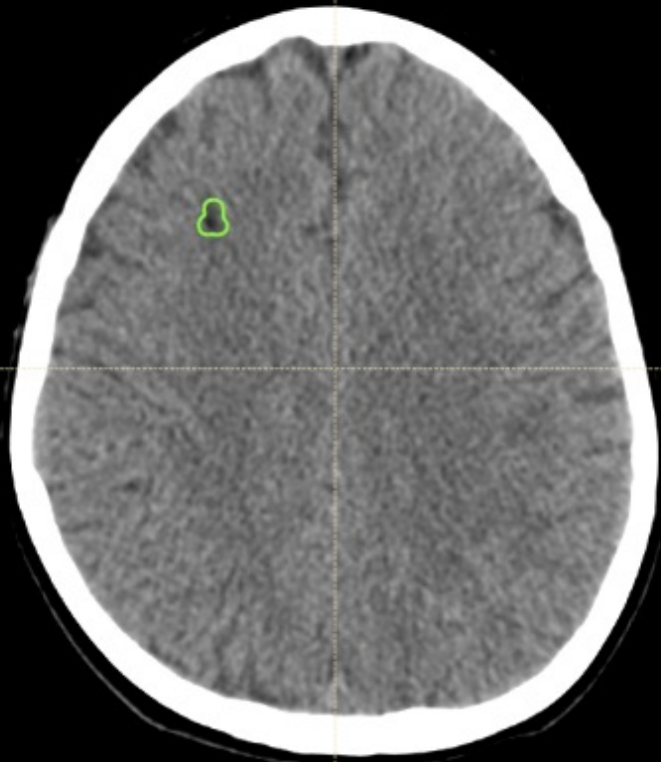
Navigation icons: Home, Search, and other controls.



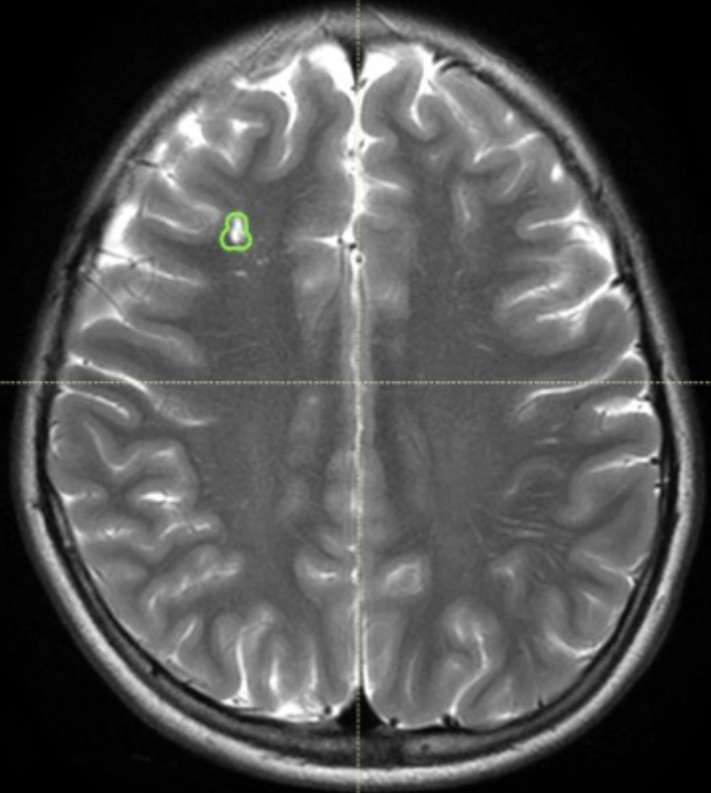
0 1 2 3 4 cm



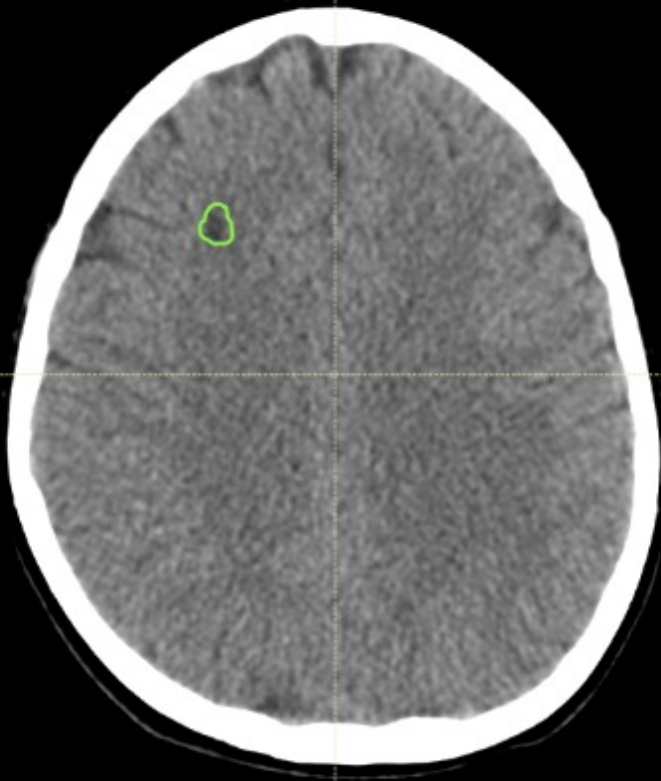
0 1 2 3 4 cm



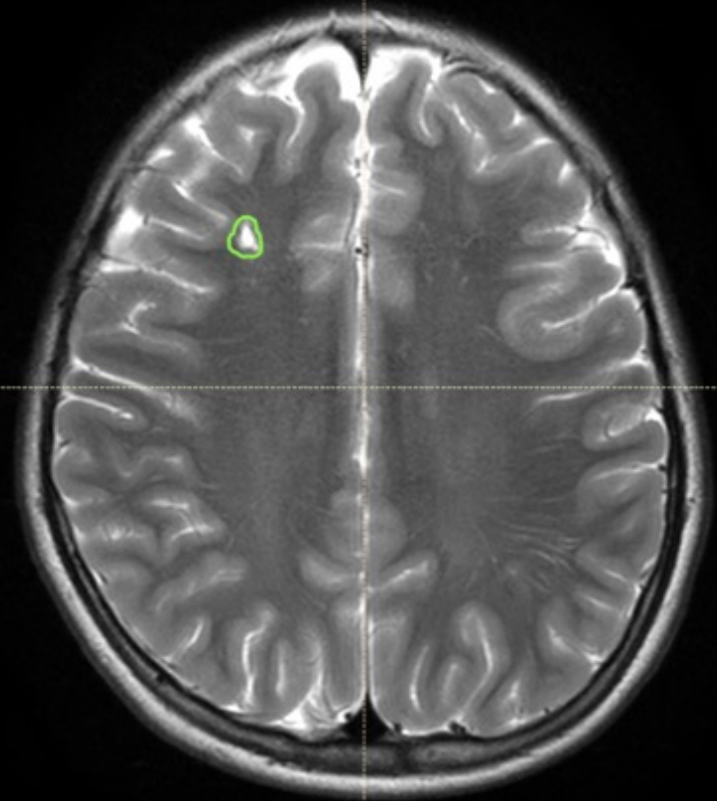
Navigation icons: Home, Search, Refresh, Close



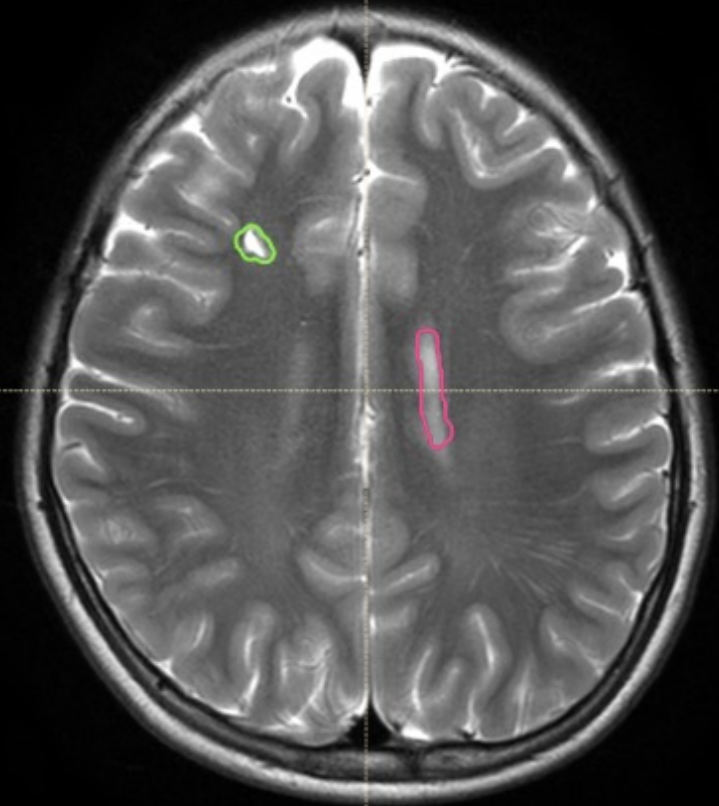
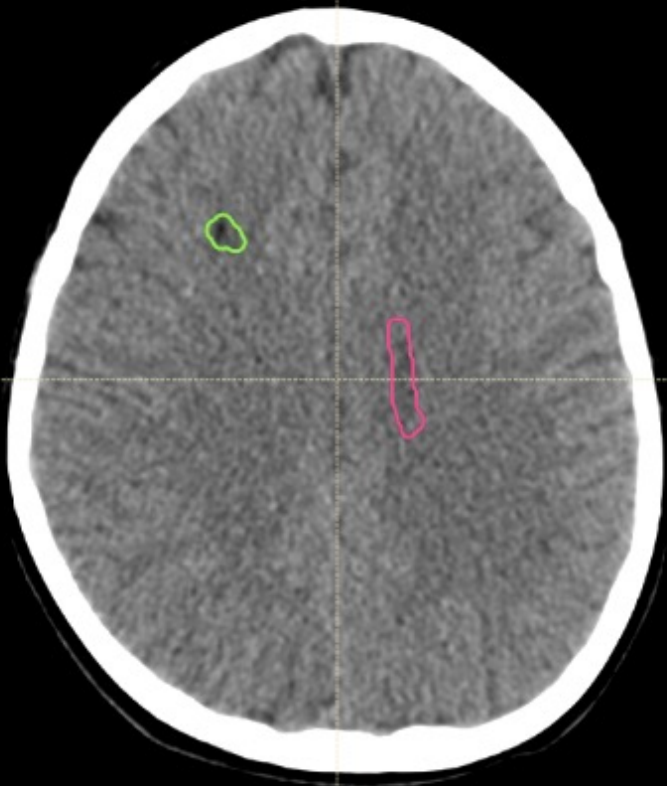
Navigation icons: Home, Search, Refresh, Close

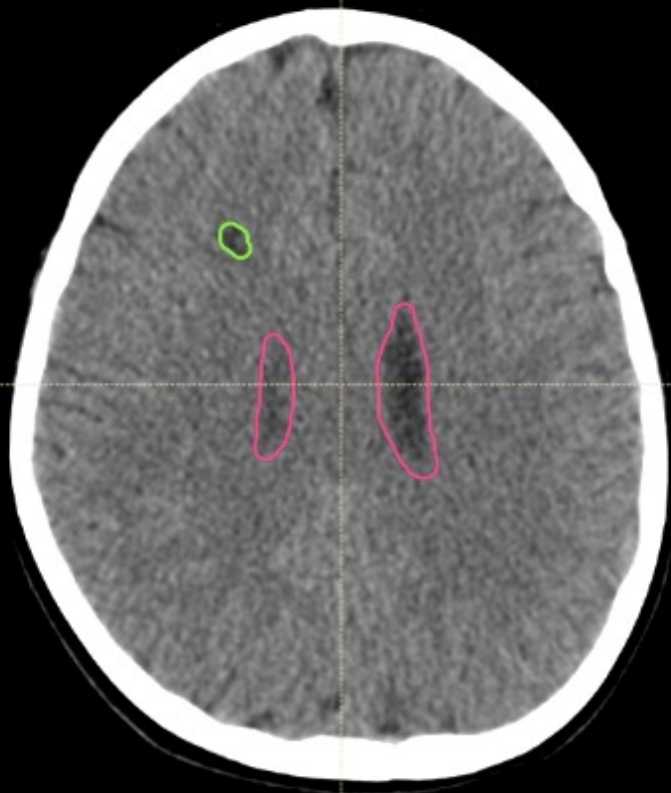


放大 0 00

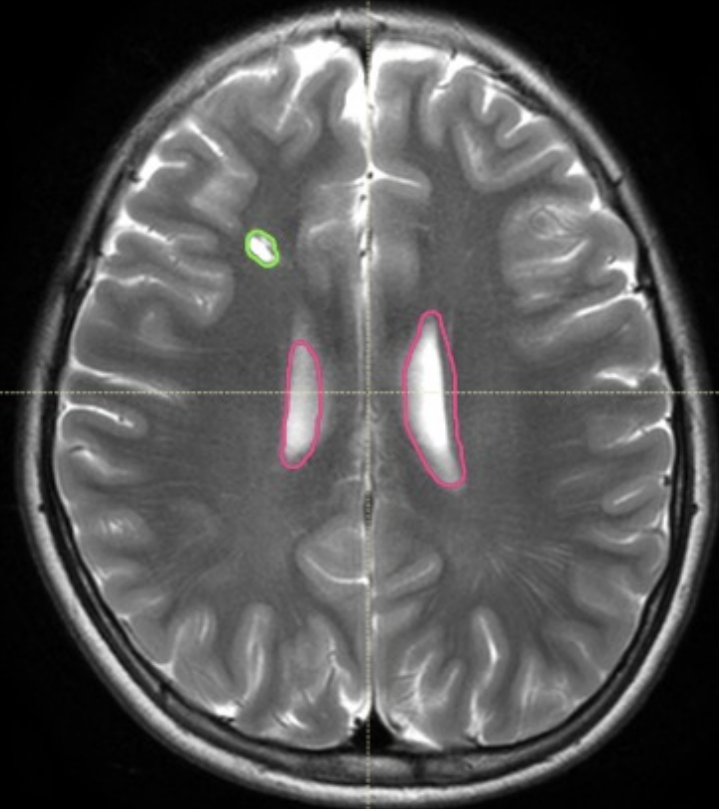


放大 0 00

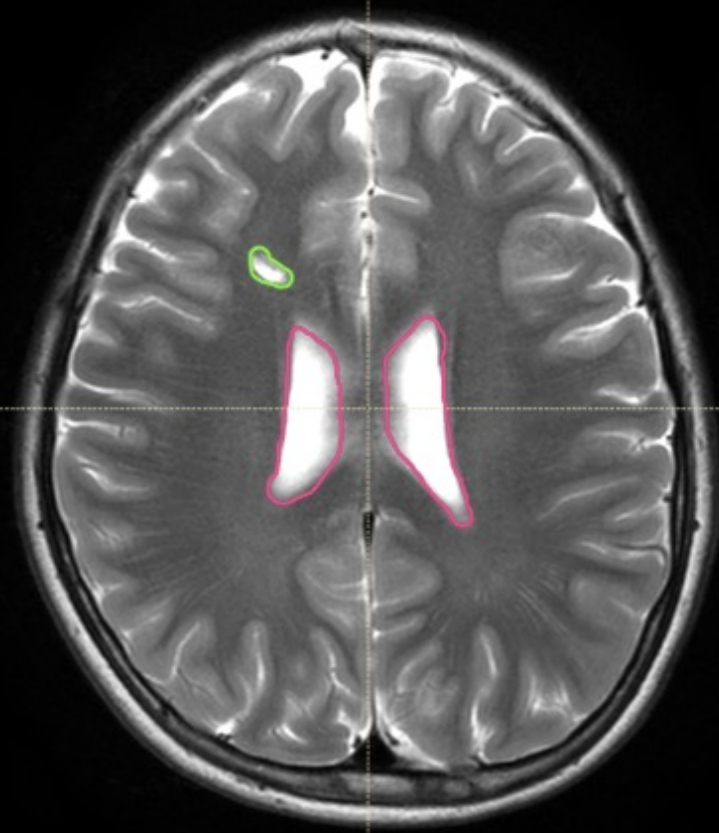
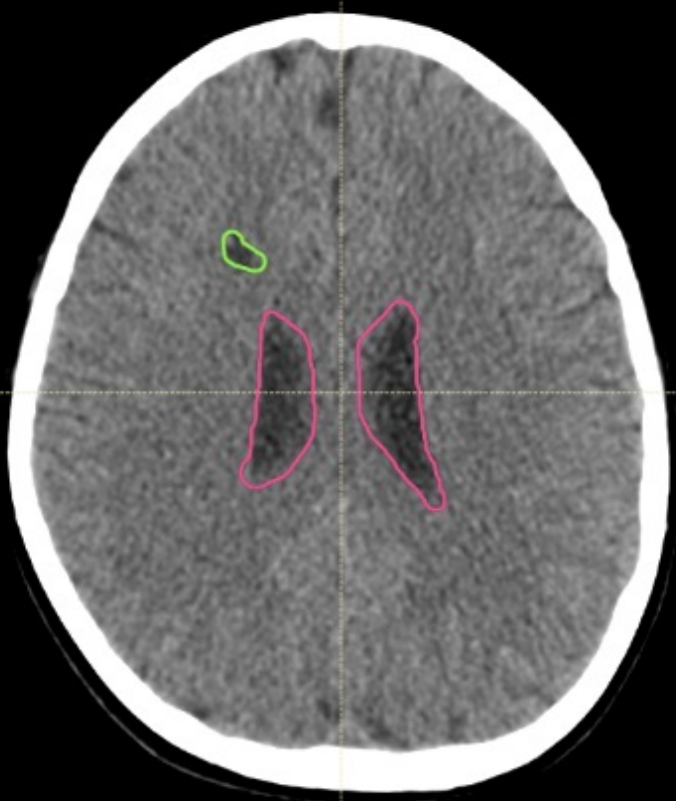

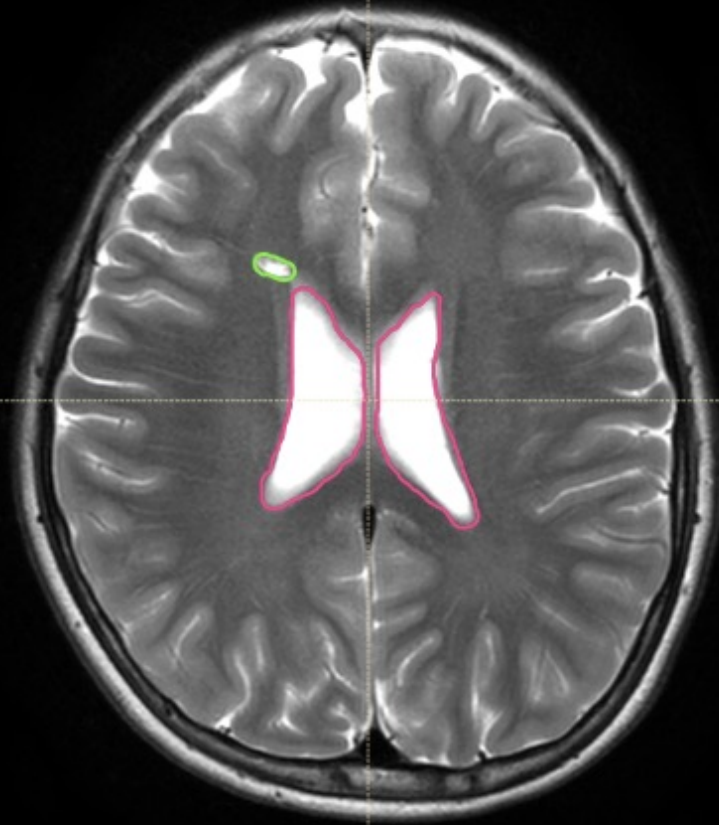

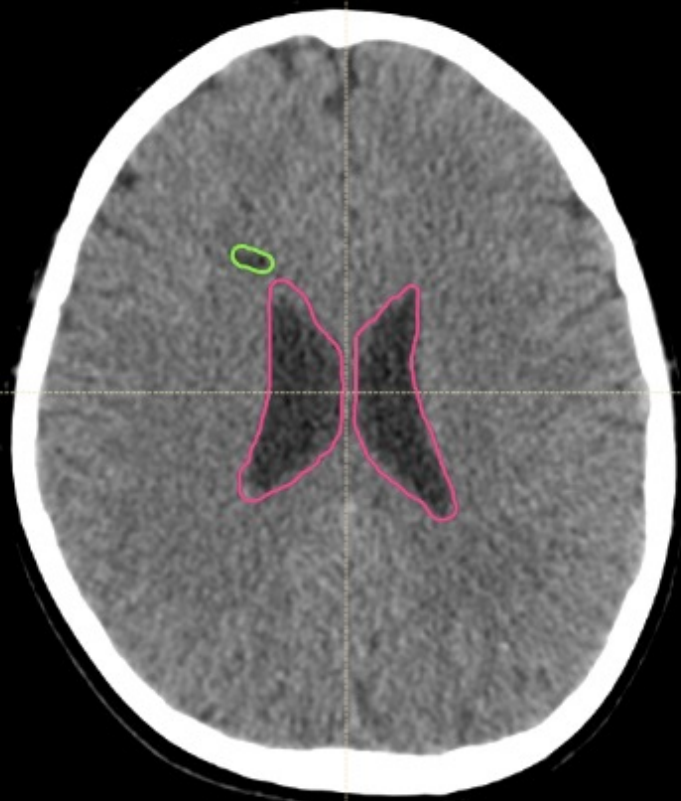
0 1 2 3 4 cm

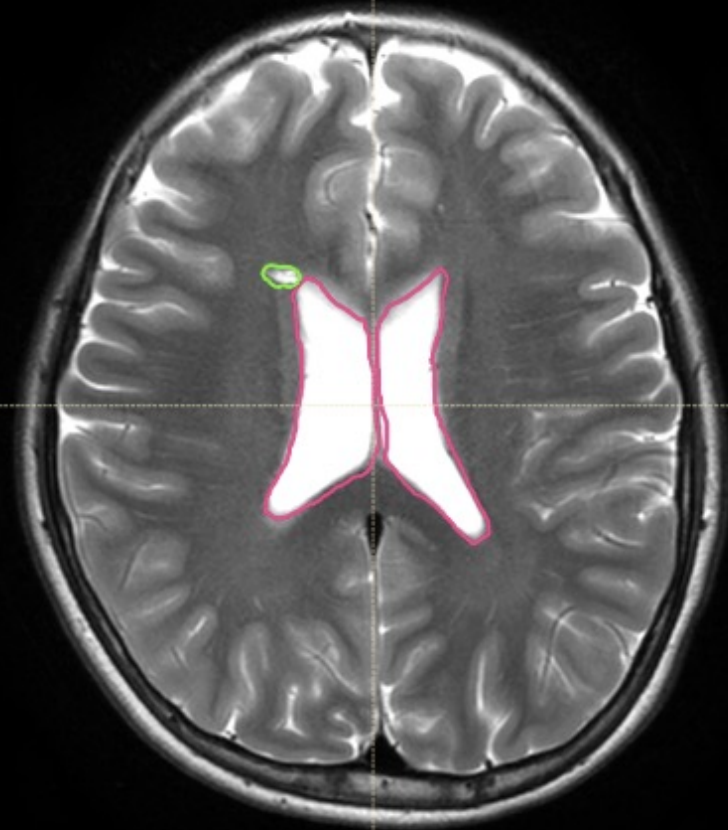
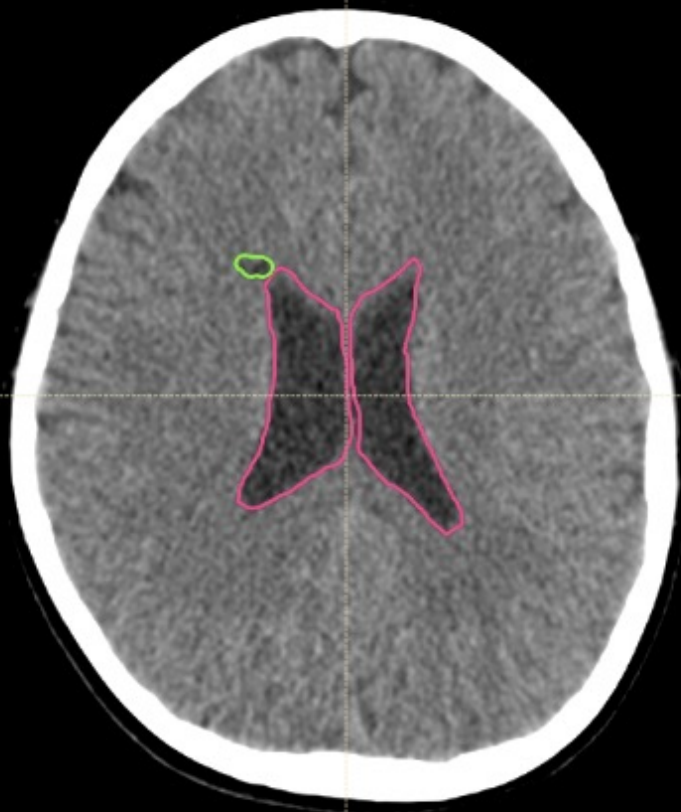
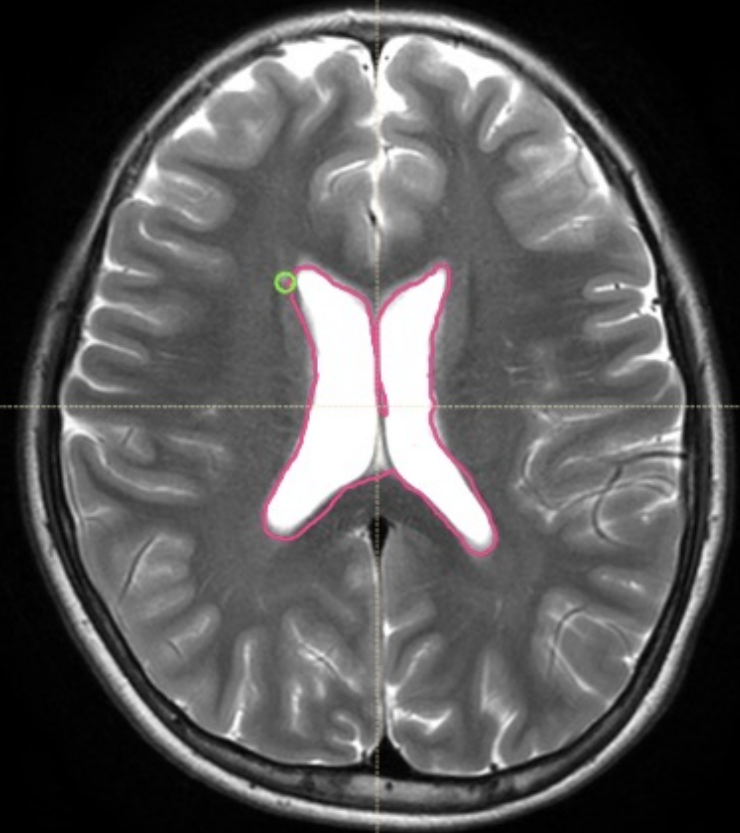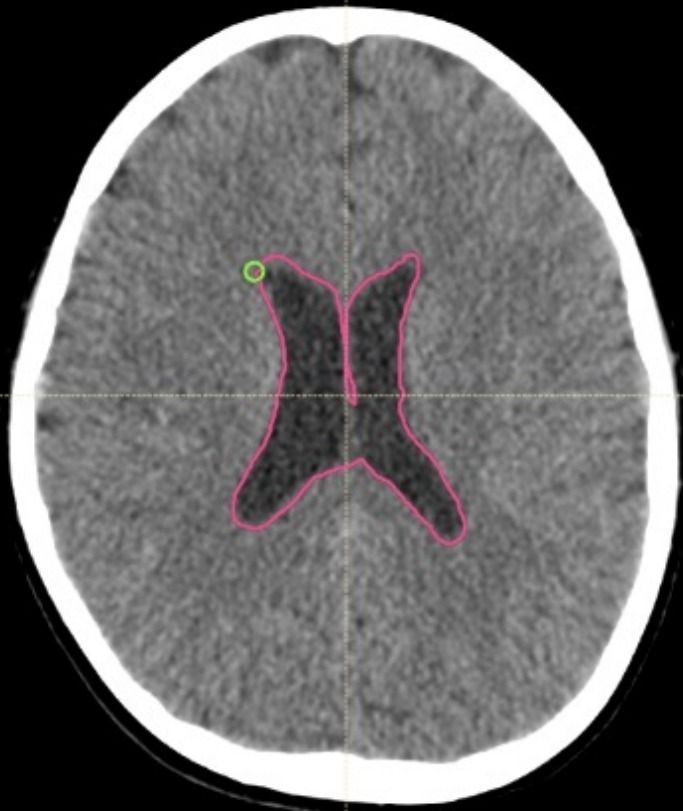0 1 2 3 4 cm

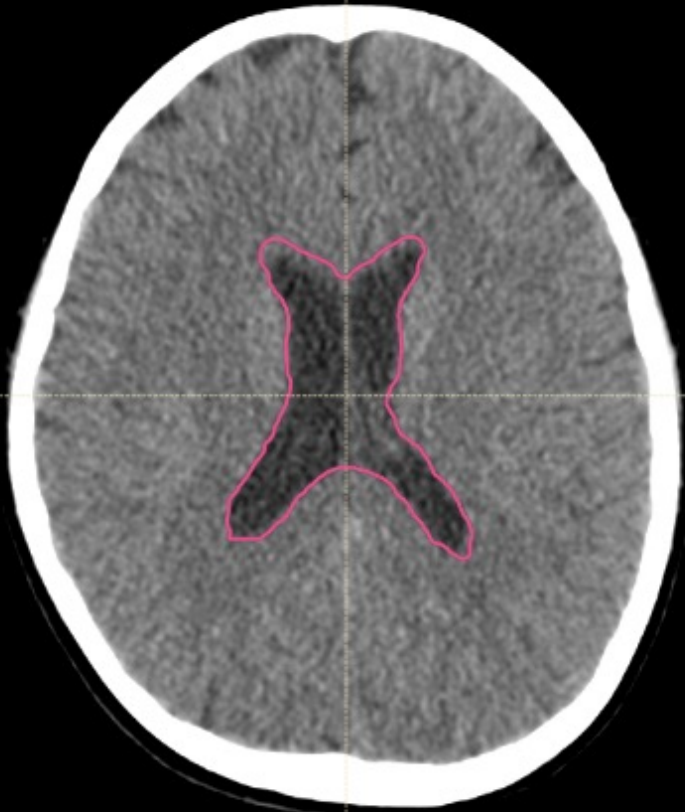




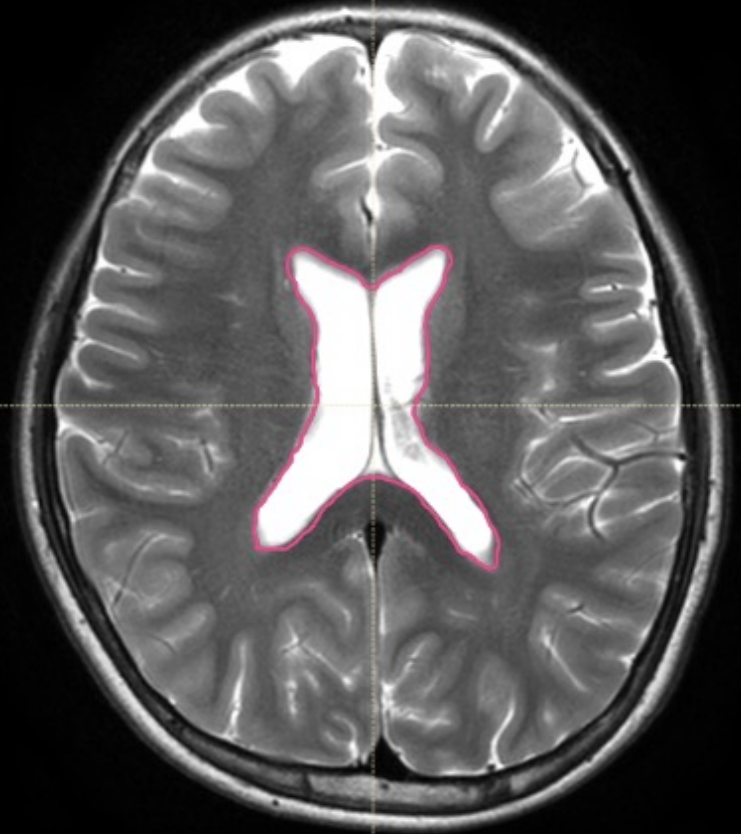






0 1 2 3 4 cm



0 1 2 3 4 cm

Spinal canal (thecal sac)

Section c)

# Spinal canal (thecal sac)

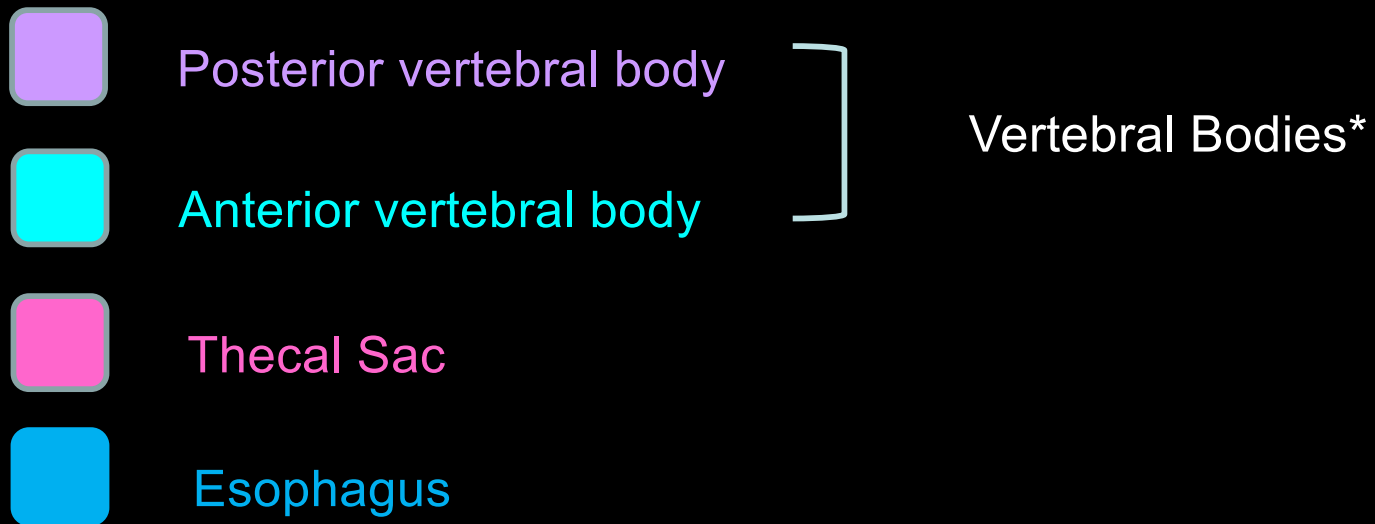
- The superior slice of the CTV\_Spine should match the inferior slice of CTV\_WVV.
- The inferior slice of CTV\_Spine should be placed after reviewing spine MRI, and is 1.5 cm below the thecal sac
  - At least S2-S3 interspace, but may be as low as the inferior border of S4
- CTV\_Spine will extend laterally on both sides to cover the recesses of the entire vertebral bodies.

# Vertebral bodies

- The “Vertebral Bodies” volume should include the anterior and posterior elements of C2-L5.
  - Inclusion of the sacrum is optional.

# Skeletally immature children

- Treatment of vertebral bodies is made at the discretion of the radiation oncologist.
- If vertebral bodies are treated, then CTV\_VB\_1800 will be created, which is equal to Vertebral Bodies.
- The PTV\_VB\_1800 is equal to CTV\_VB\_1800 (0 mm expansion).

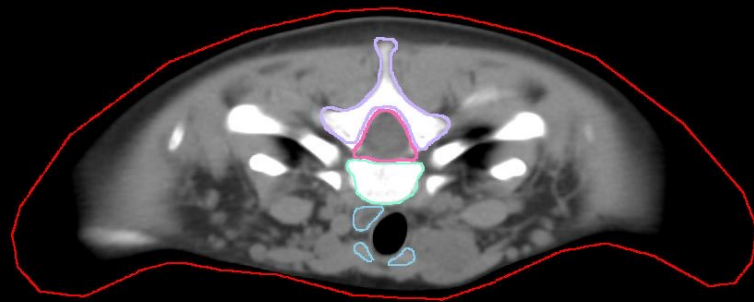


\*Separating the Vertebral Bodies contour into posterior and anterior components is optional.



P

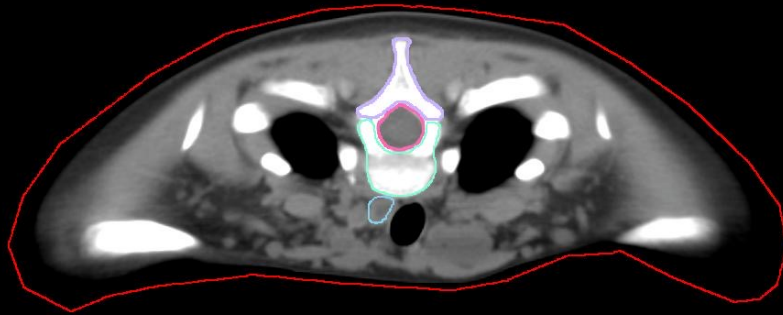
-143.75 mm  
98



R

P

-147.5 mm  
97



R

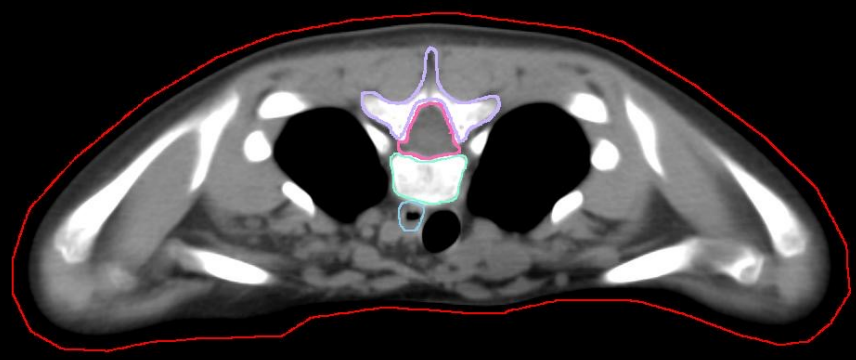
A

L



P

-155 mm  
99



L

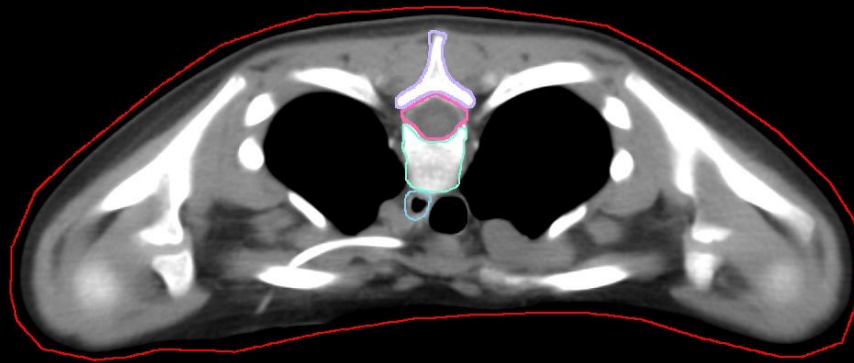
R

A



P

-162.5 mm  
93

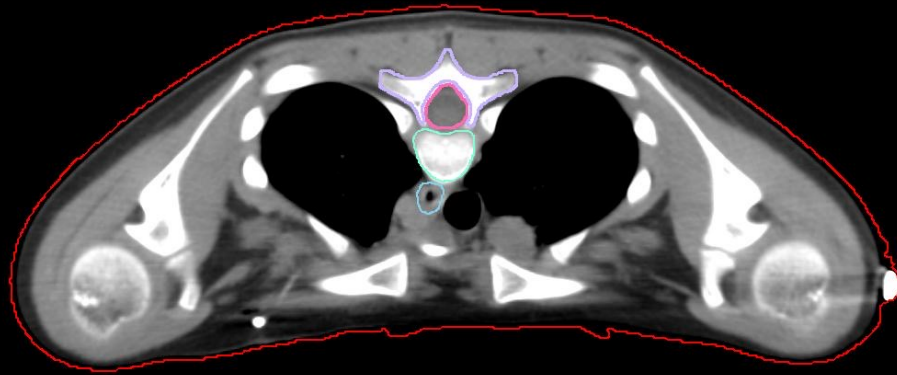


R

A

P

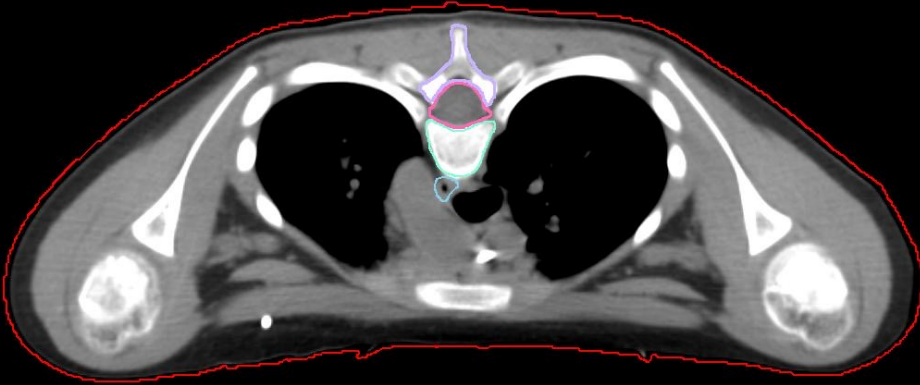
-170 mm  
31



A

P

-181.26 mm

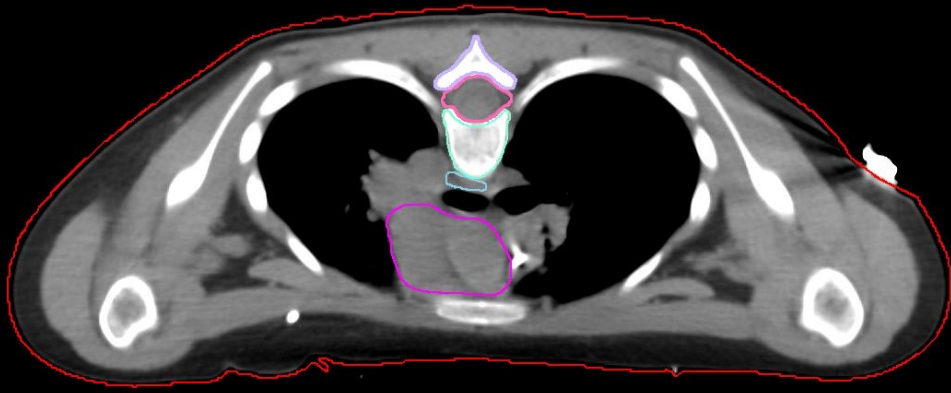


R

A

P

-192.51 mm  
85

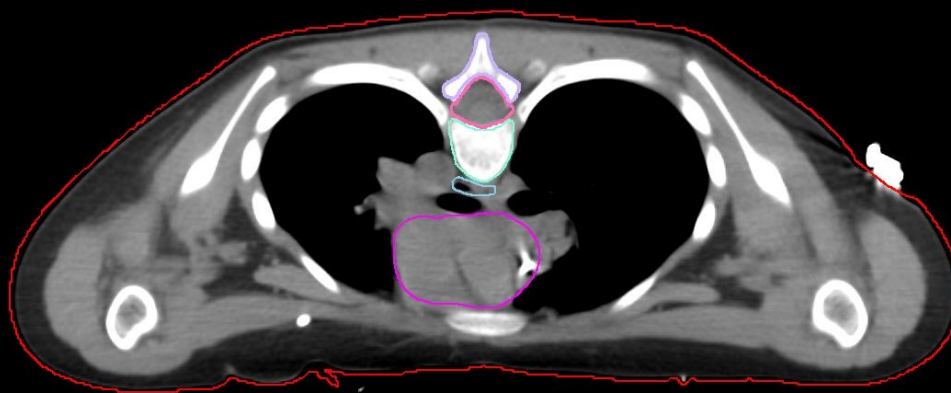


R

A

P

-196.26 mm  
84



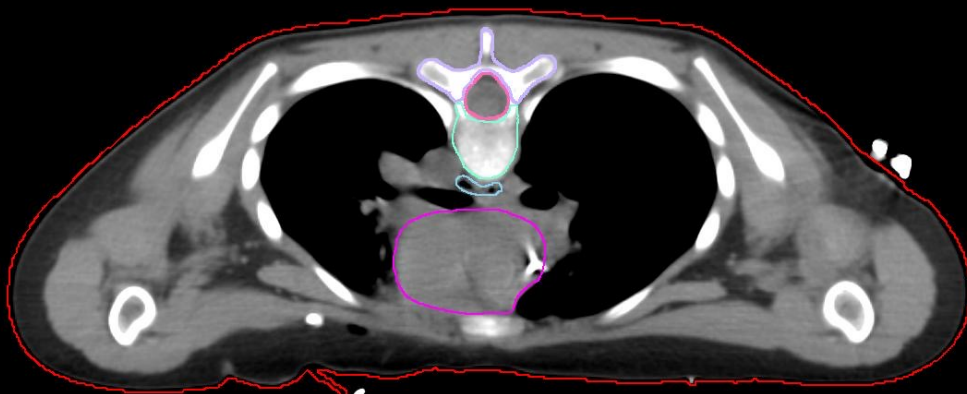
R

A



P

-200.01 mm  
83



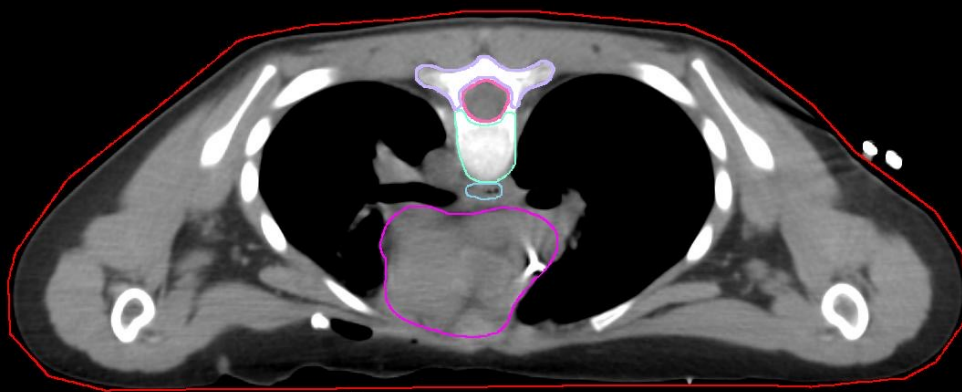
R

A

P

-203.76 mm

32



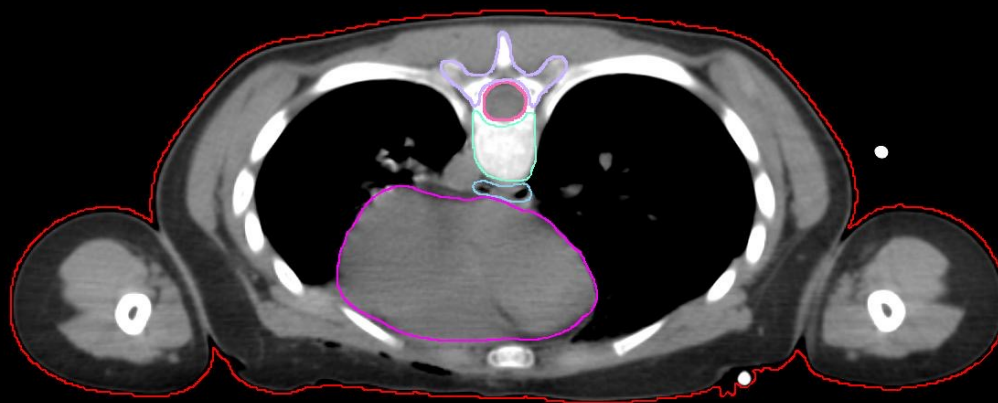R

A

P

-233.76 mm

74



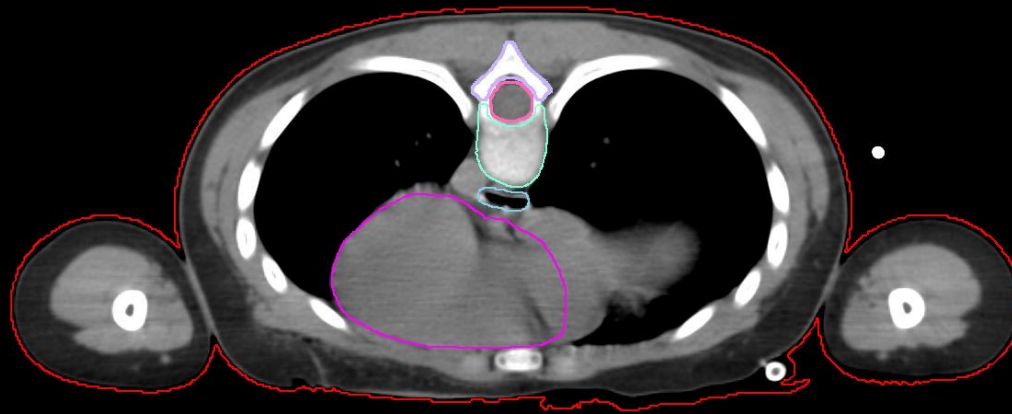
L

R

A

P

-248.77 mm  
70

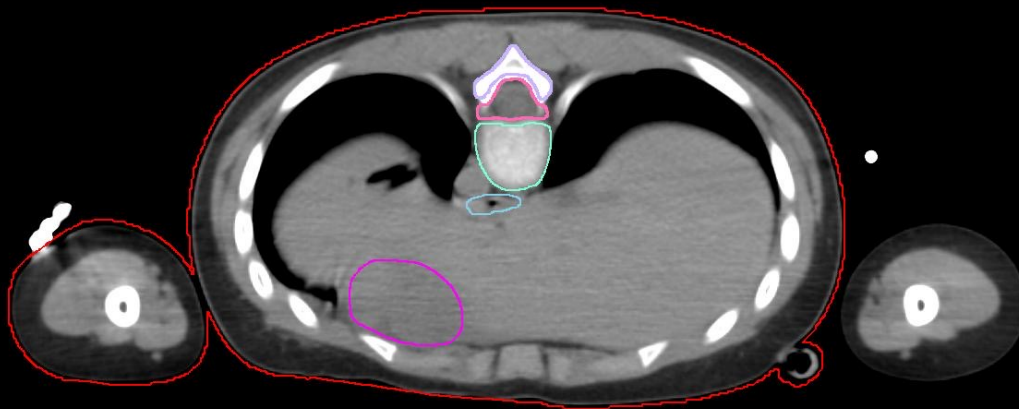


A



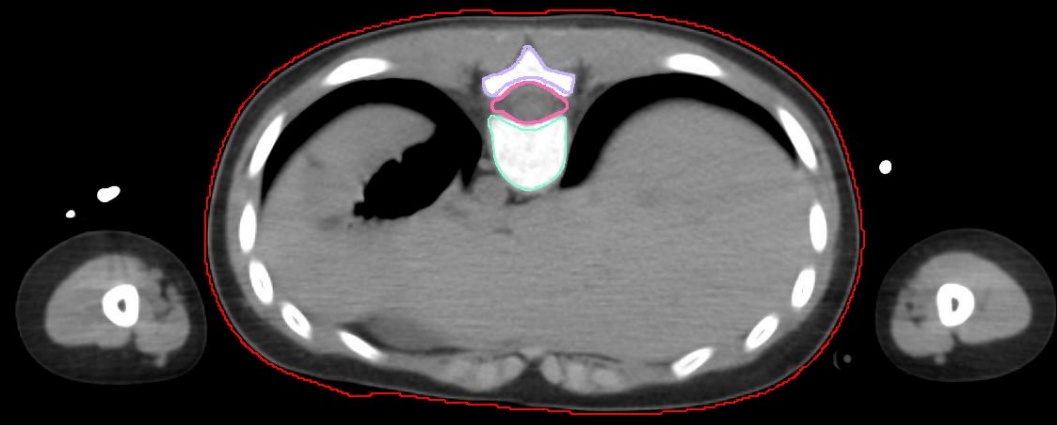
P

-263.77 mm  
66



A

P



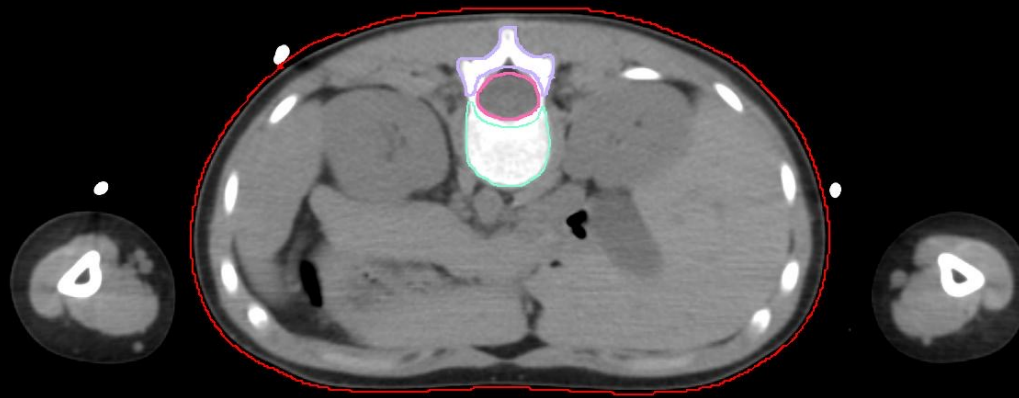
L

A



P

-327.53 mm  
49

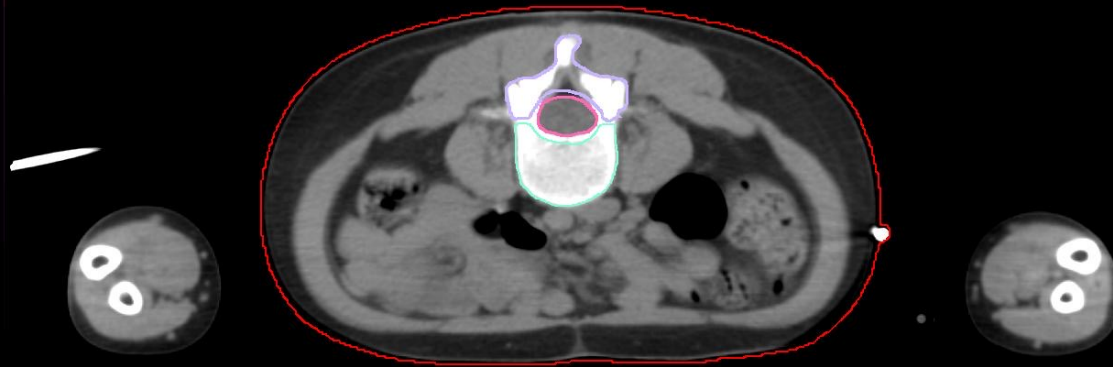

R

A

P

-398.79 mm  
30



L

R

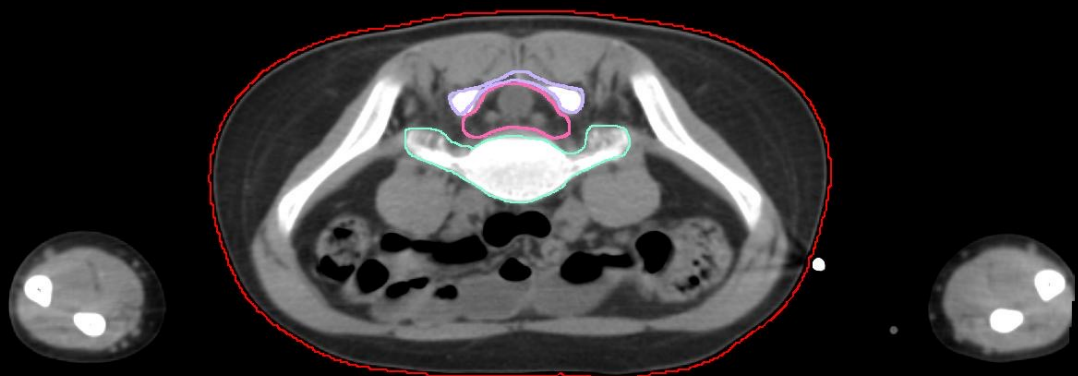
A



P

-432.54 mm

21

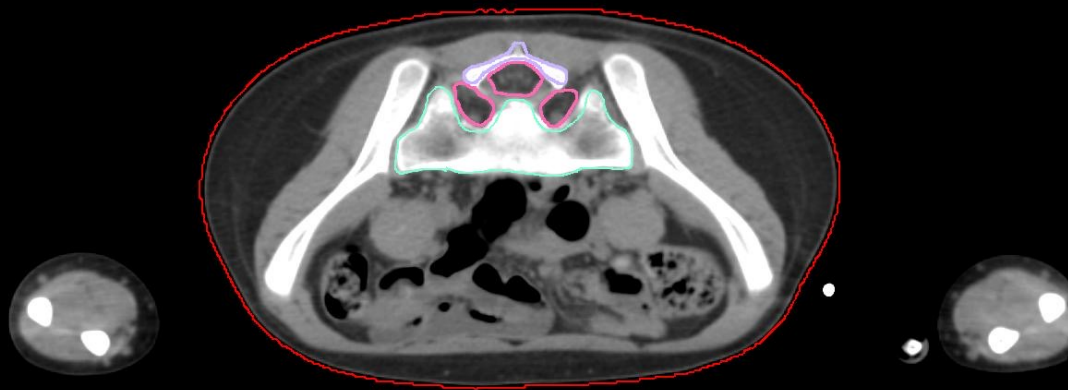


R

A

P

-451.29 mm  
16

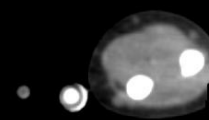
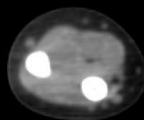
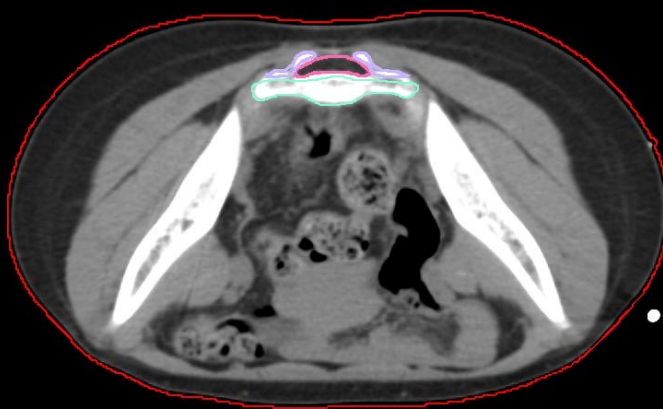


R

A

P

-473.8 mm  
10



A

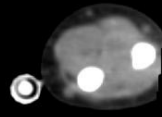
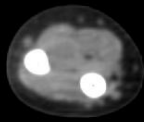
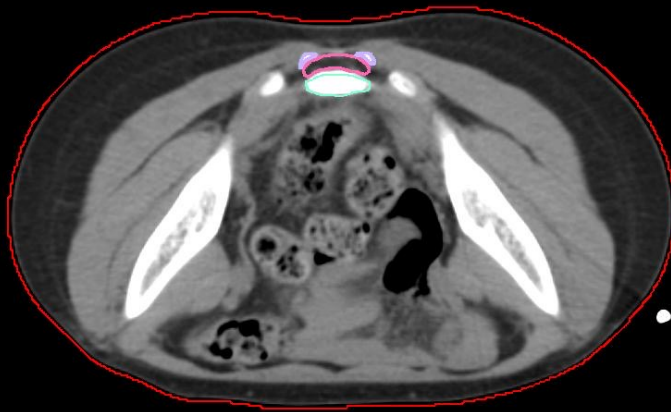L

R



P

-477.55 mm  
9

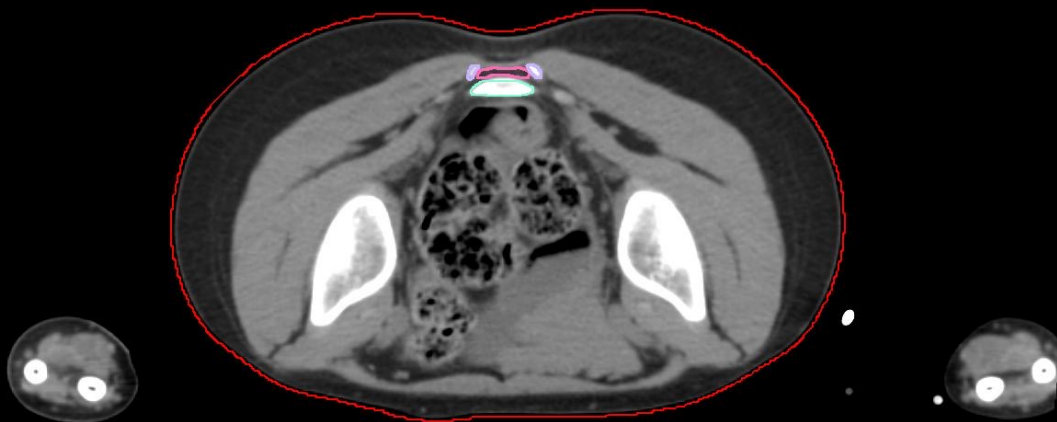


A



P

-492.55 mm  
3



A

